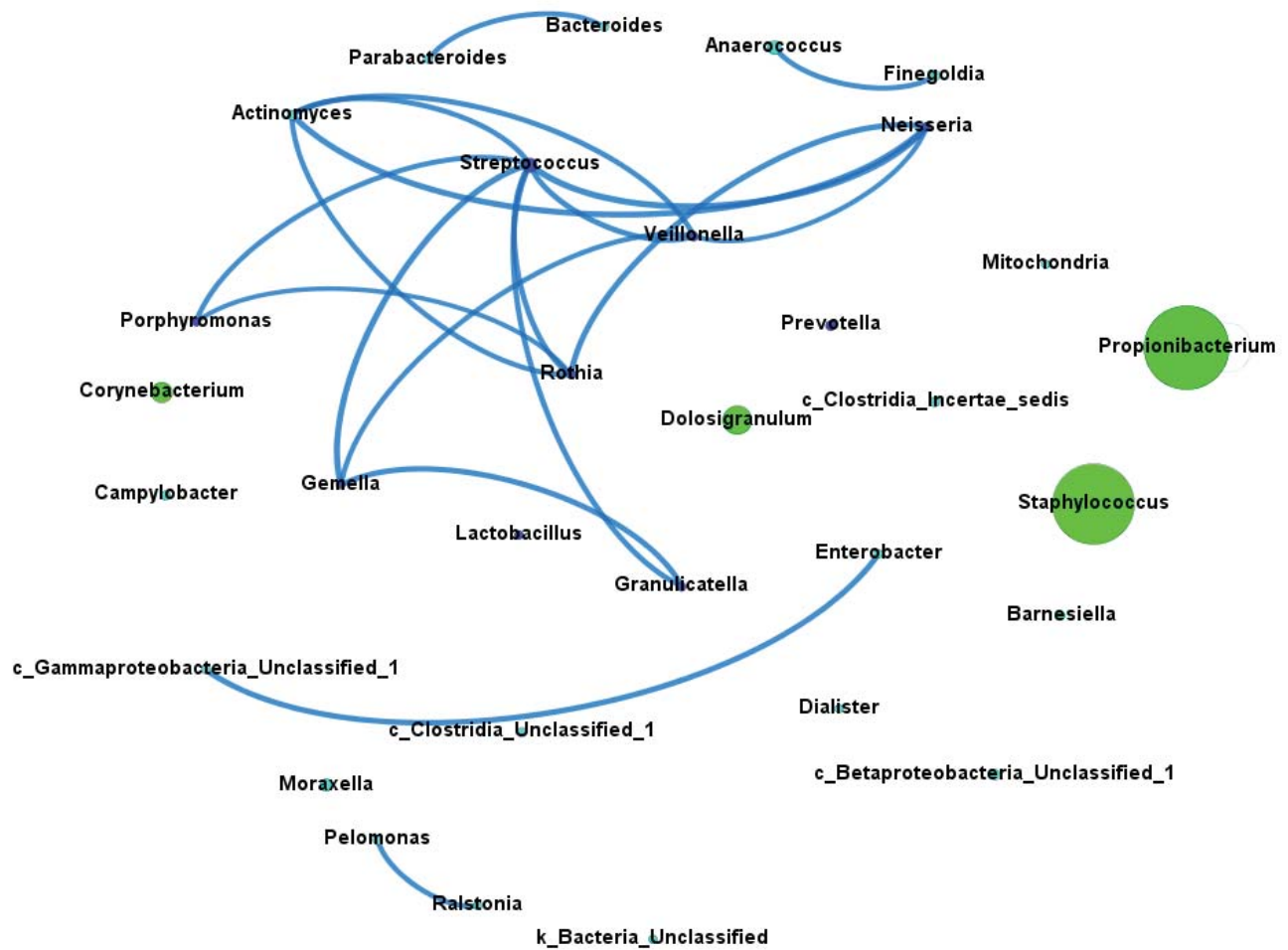
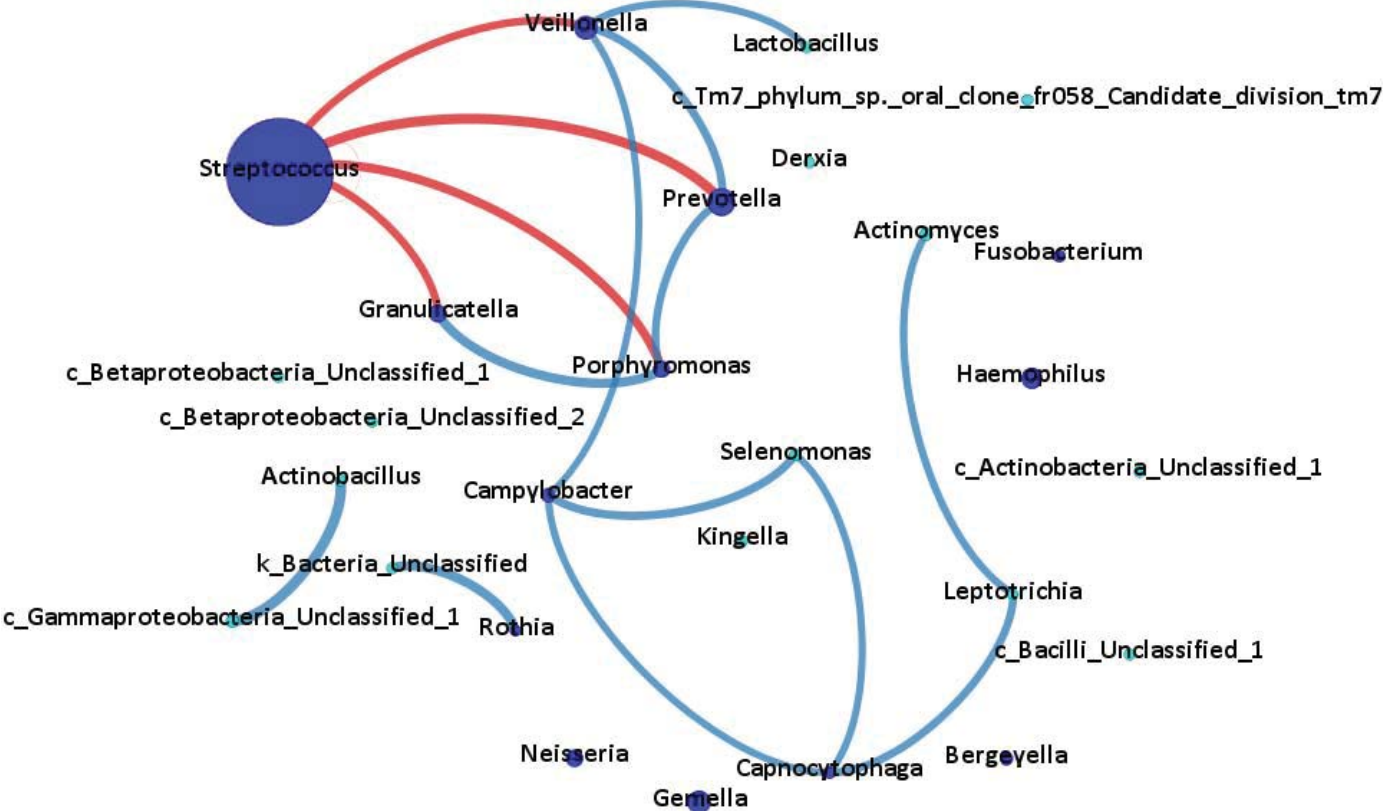


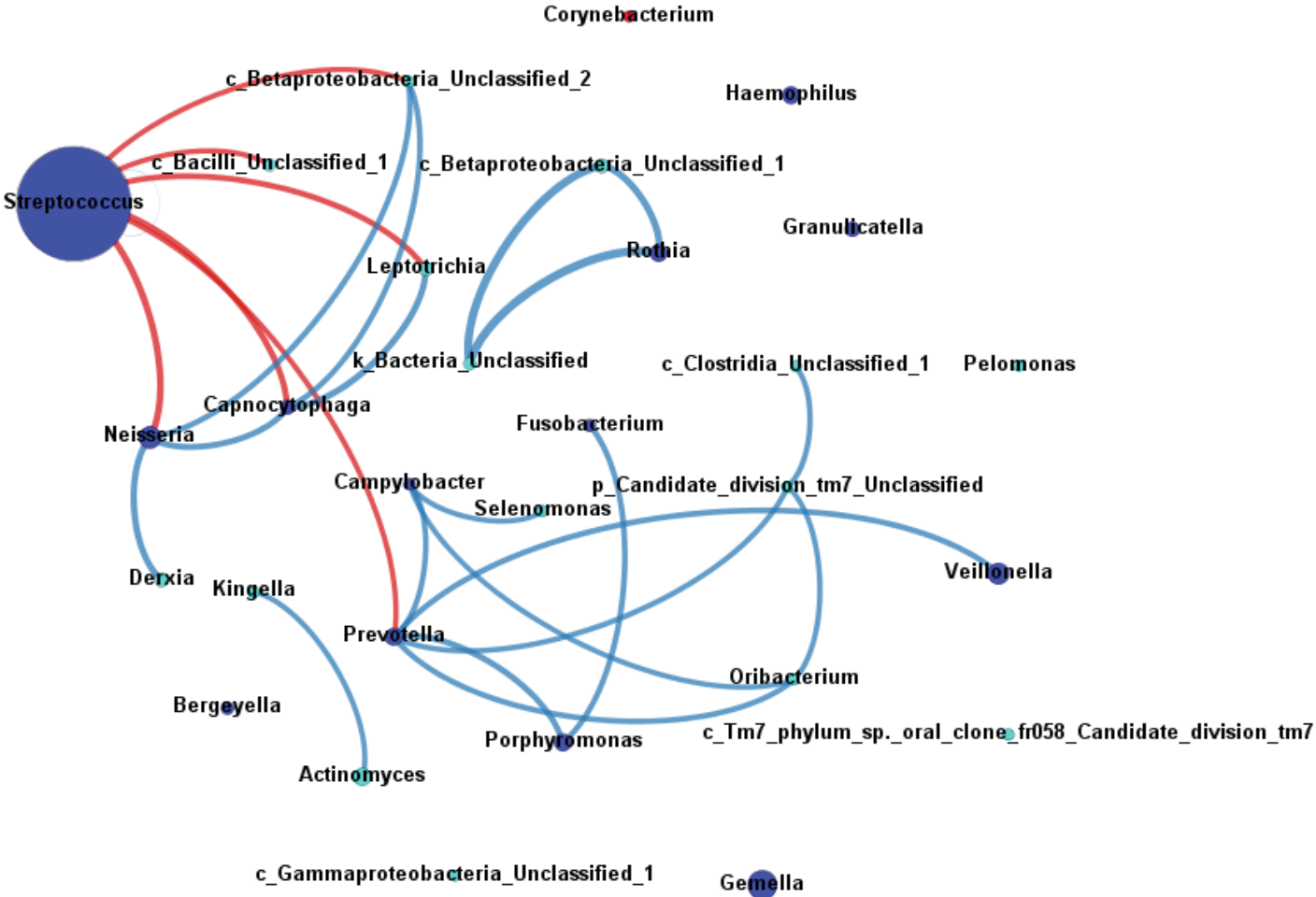
a – Anterior nares



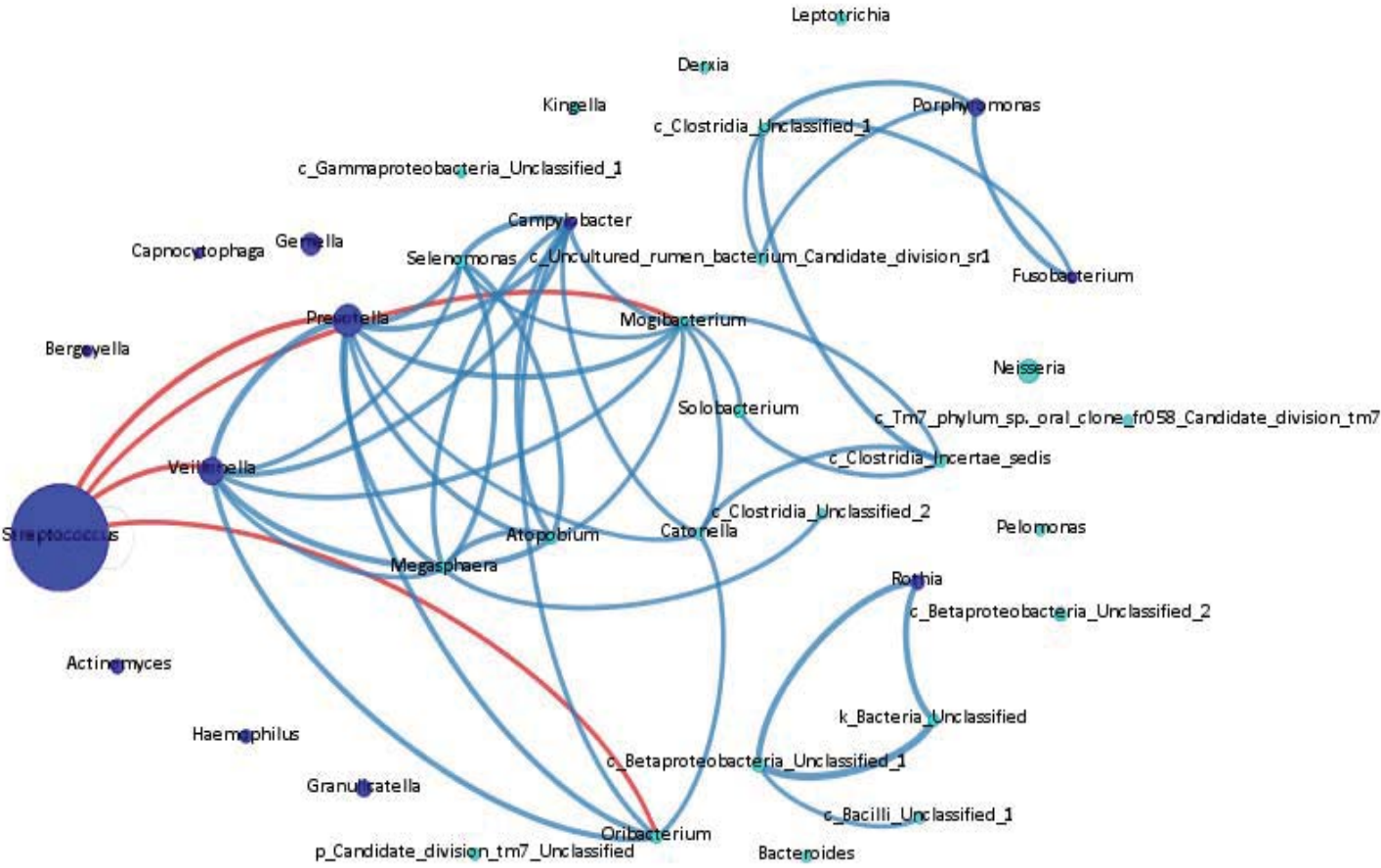
b – Attached Keratinized Gingiva



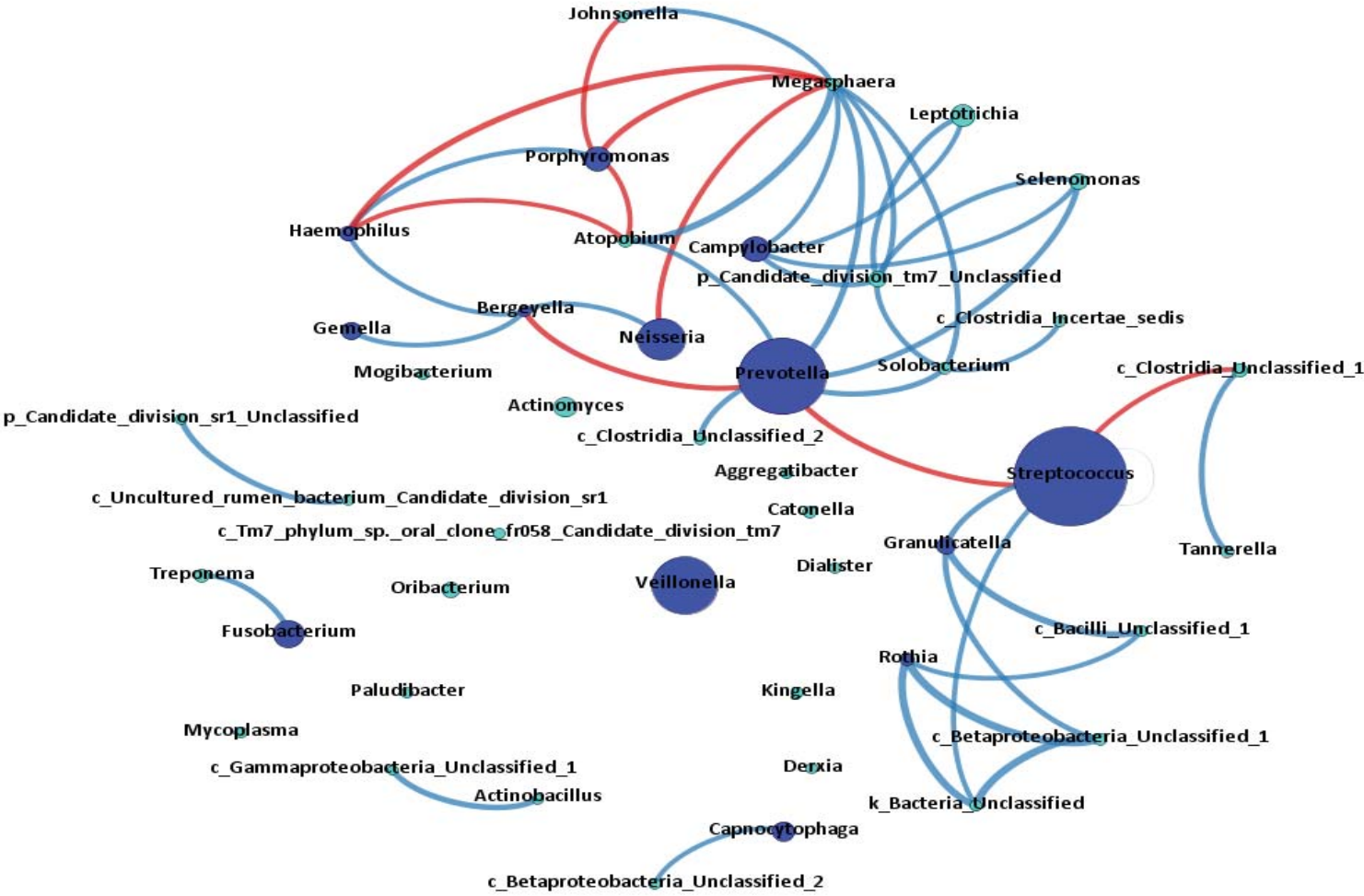
c – Buccal Mucosa



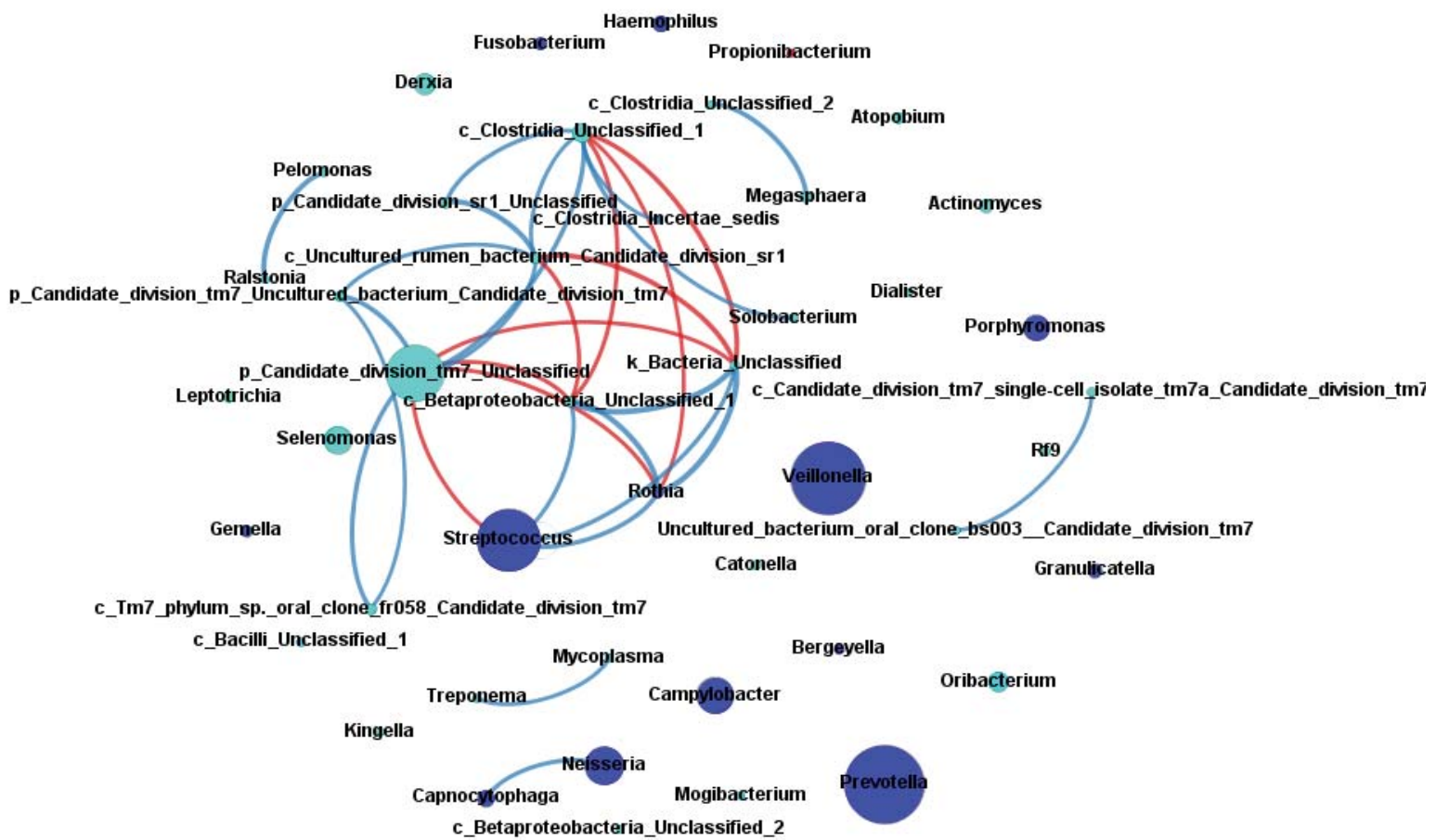
d – Hard Palate



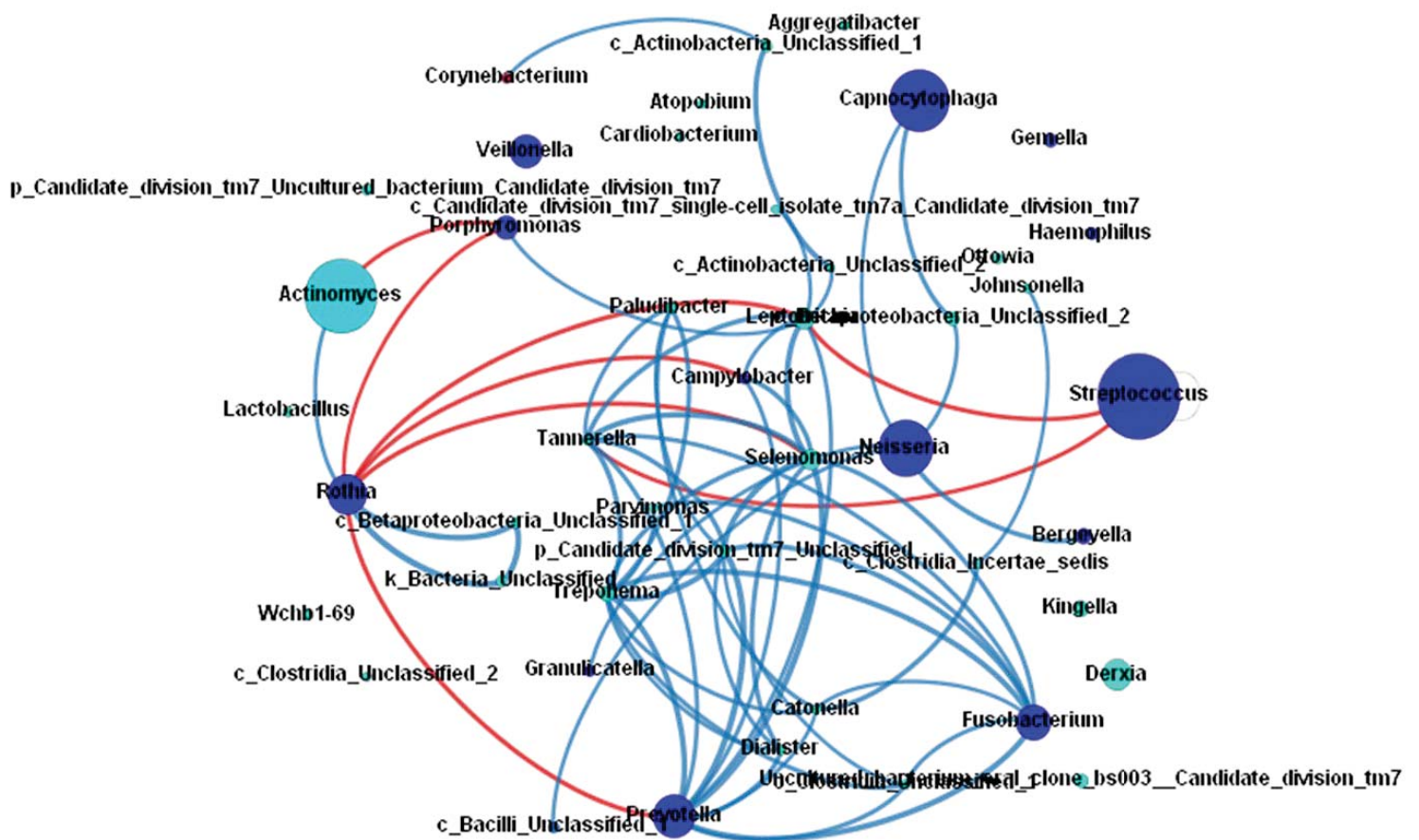
e – Palatine Tonsils



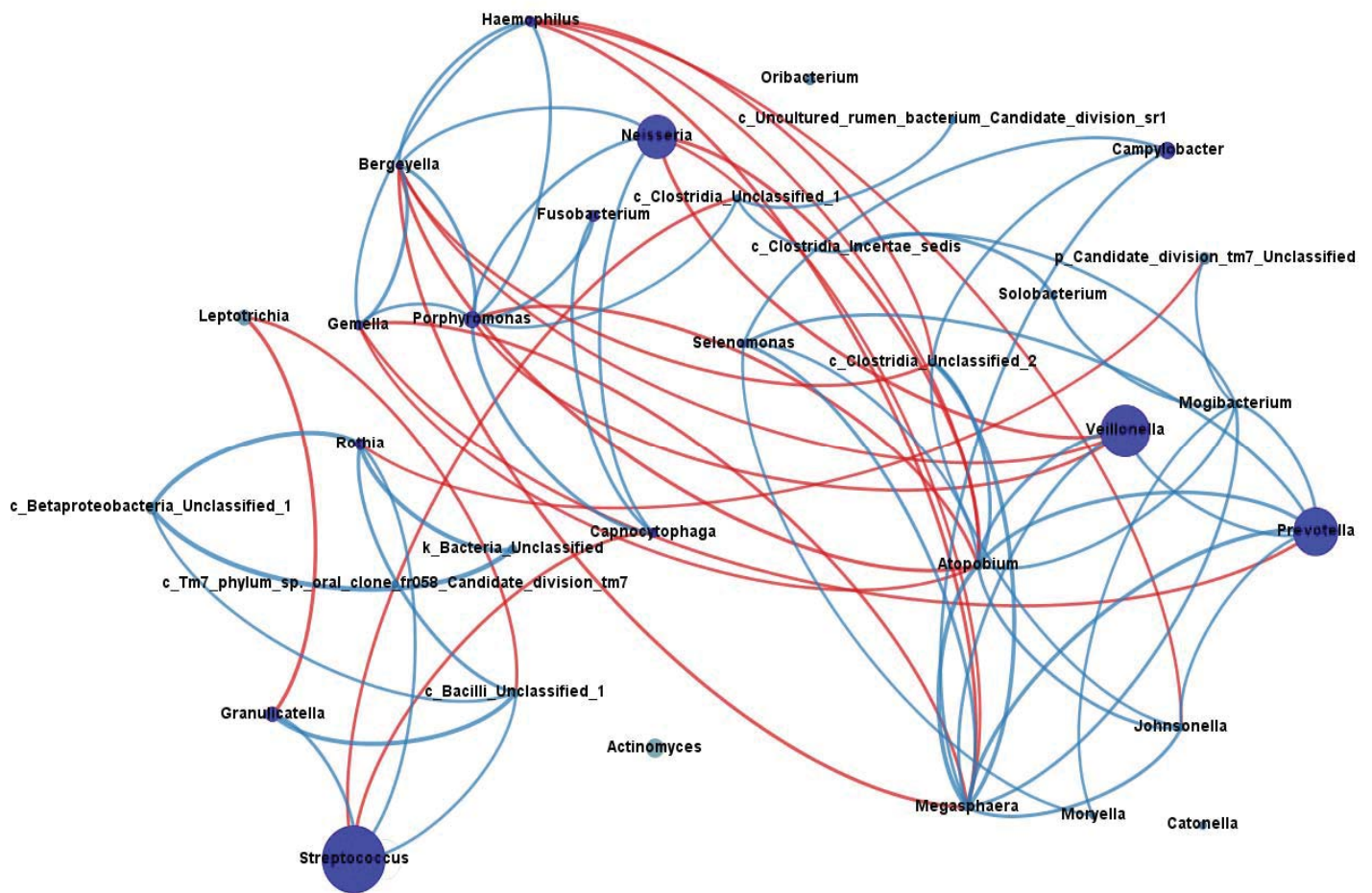
f – Saliva



g – Subgingival Plaque



i – Tongue Dorsum



j – Throat

