



Idiopathic pulmonary fibrosis: airway volume measurement identifies progressive disease on computed tomography scans

To the Editor:

Idiopathic pulmonary fibrosis (IPF) is a progressive condition with unclear aetiology and patients decline with heterogeneous trajectories. Whilst antifibrotic therapy can slow disease progression [1, 2], the ability to determine an individual's disease course is limited to measurement of pulmonary function (pulmonary function testing (PFT)) and visual assessment of computed tomography (CT) scans, both of which have limitations. PFT is affected by patient technique and operator experience [3]; CT scans rely on radiologist expertise to correctly interpret disease stability/progression and are subject to interobserver variability [4]. Recently, automated analysis of blood vessel volume has been shown to predict disease progression [5]. We hypothesised that a novel measurement of airway volume using functional respiratory imaging (FRI) could identify CT scans with more progressive disease. FRI is a semiautomated technique for segmenting thoracic CT anatomy, including airways up to the seventh generation, combined with flow simulation to derive volume and resistance measurements [6]. Images are usually compared at full inspiration (total lung capacity (TLC)) and functional residual capacity (passive expiration) for resistance calculations. However, imaging at TLC alone is sufficient to measure lung and airway volume. The robustness of FRI has been validated in obstructive airway disease, and in IPF has been explored in a small number of patients as part of a phase IIa trial of pamrevlumab [6] and phase IIa trial for the autotaxin inhibitor GLPG1690. Whilst this second study was not powered to show a change in forced vital capacity (FVC), differences were seen in airway volume and resistance in those treated with the medication compared with placebo, but the placebo group was limited with only three patients [7].

We performed a sequential database analysis to identify two separate cohorts (n=12 per group) of IPF patients (hereby termed "stable" or "progressive") from a specialist centre in the UK. The aim was to determine if, between two CT timepoints, FRI could distinguish between patients with more evidence of clinoradiological disease progression. Inclusion criteria were multidisciplinary team (MDT) diagnosis of IPF, treatment naivety to antifibrotic therapy and two CTs of sufficient quality (determined by an expert thoracic radiologist) ≥ 3 months apart, with PFT in close association (within 3 months) with each CT. Exclusion criteria were forced expiratory volume in 1 s/FVC < 0.7 , significant other respiratory pathology including emphysema $> 15\%$ on CT (as determined by radiologist) or evidence of IPF exacerbation at the time of CT.

Patients were assigned to the stable group if there was a $\leq 10\%$ absolute FVC decline between CTs and clinoradiological evidence of disease stability confirmed at repeat MDT. Patients were assigned to the progressive group if there was a $\geq 10\%$ absolute FVC decline between CTs and evidence of progression, again confirmed by MDT. All CT data were anonymised and underwent FRI analysis (figure 1a). Analysts were blinded to clinical information. Lung and airway volumes were available for total lung, individual



@ERSpublications

Airways tell a tale: measuring change in airway volume using functional respiratory imaging can differentiate between stable and progressive idiopathic pulmonary fibrosis on CT scans
#imagebiomarkers #ipf <http://bit.ly/2M8KVLl>

Cite this article as: McLellan T, George PM, Ford P, *et al.* Idiopathic pulmonary fibrosis: airway volume measurement identifies progressive disease on computed tomography scans. *ERJ Open Res* 2020; 6: 00290-2019 [<https://doi.org/10.1183/23120541.00290-2019>].

Copyright ©ERS 2020. This article is open access and distributed under the terms of the Creative Commons Attribution Non-Commercial Licence 4.0.



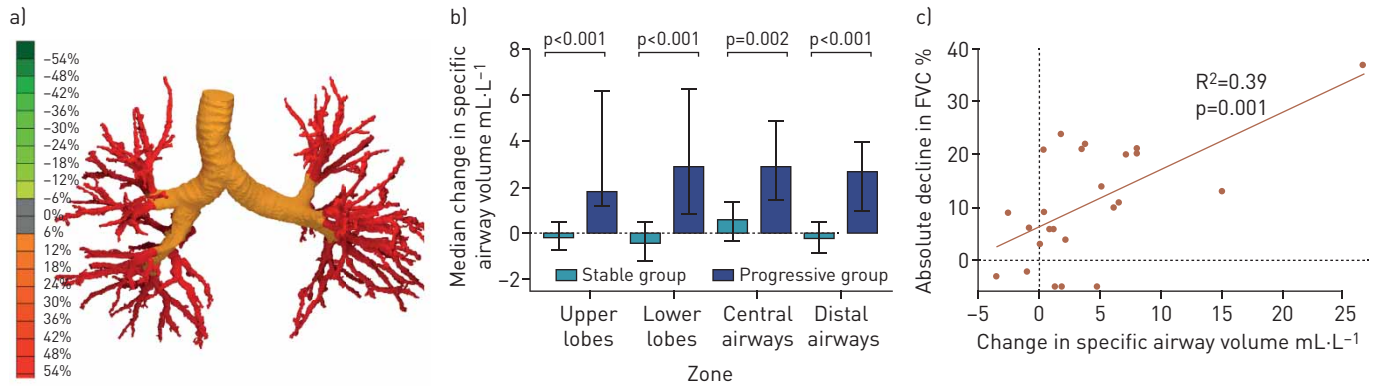


FIGURE 1 a) Specific airway volume change between computed tomography scans in an example patient. b) Median change in specific airway volume in the stable and progressive groups. The error bars represent the interquartile range and the bars themselves the median change. c) Correlation between absolute decline in forced vital capacity (FVC) (% predicted) with change in total specific airway volume.

lobes, central (first to second generation) and distal (third to seventh generation) airways. Specific airway volume (siV_{aw}) was calculated by dividing the airway volume by lung volume. This allowed for interpatient comparison of airway volume in patients with different lung volumes and inpatient comparison, given that lung volumes were expected to decline between imaging [4]. The study was approved by the ethics committee at our institution (ref. S02467). Initial statistical analysis was performed using R version 3.6.1 (R Foundation for Statistical Computing, Vienna, Austria); diagrams and between group comparisons using Prism v.8.1.1 (GraphPad, La Jolla, CA, USA).

Both groups were matched for both demographics and baseline PFTs. There was no difference ($p=0.5$) between groups in the timing of CT to PFT; the majority were performed within 2 months of imaging. The interval between imaging varied between 174 and 1059 days (median interval 366 (stable) and 695 (progressive) days, $p=0.05$). Both groups exhibited decline in FVC between CT scans with a smaller median drop in the stable group (-140 mL) versus the progressive group (-400 mL) ($p=0.005$). Similar findings were observed in change in transfer factor of the lung for carbon monoxide between groups (stable -7% , progressive -17% ; $p=0.02$). To support the changes in FVC, there was a decline in FRI lung volume in both groups. This was smaller in the stable (-270 mL) versus the progressive (-740 mL) group ($p=0.03$).

We used random forest analysis and out-of-bag cross-validation to identify FRI parameters that best distinguished between groups (corrected and uncorrected airway/lung volumes and resistance measured overall and in individual lobes; minimum nodes 1, maximum 48). There were seven parameters with a Gini index >0.65 and within these parameters, the siV_{aw} measurements were more predictive at distinguishing between groups than uncorrected airway volumes.

At first CT scan, median airway volumes for stable and progressive groups were similar at 53 and 60 mL respectively, with total siV_{aw} values of 14.9 and 15.6 $\text{mL}\cdot\text{L}^{-1}$ (Kruskal-Wallis, $p=0.48$). There was then a significant increase in the siV_{aw} of the progressive group (median change $+6$ $\text{mL}\cdot\text{L}^{-1}$) compared with the stable group (median change -0.57 $\text{mL}\cdot\text{L}^{-1}$) ($p=0.0002$). This difference was replicated when analysis was confined to upper or lower lobes, or when comparing central or distal airways, with proportionally larger increase in distal airways (figure 1b). Regression analysis showed a weak correlation between siV_{aw} and interval change in FVC ($r^2=0.39$) (figure 1c). Change in specific airway resistance was also measured. There was a larger fall in total resistance in the progressive versus stable group but this was not statistically significant (-0.023 versus -0.001 $\text{kPa}\cdot\text{s}$, $p=0.14$).

Previous work suggested that traction bronchiectasis predicts mortality in IPF [8, 9], and its presence is associated with increased fibroblastic activity when CT and pathological samples are compared [10]. As IPF progresses, the proximal airways widen and distal airways dilate and become increasingly tortuous and cystic, possibly eventually causing honeycombing. This is due in part to traction forces caused by the collagenisation and contraction of the subpleural and epithelial extracellular matrix, but also due to the direct effect of the disease on the airway [11, 12]. The lungs experience increasing shear and strain stress during ventilation due to the interdependence between nondistensible and rigid airways, vasculature, and parenchyma [13]. At a cellular level, this process of mechanotransduction amplifies fibroblast activity [14]. We have demonstrated a link between increasing airway volume and disease progression, which adds weight to these data.

There are limitations with our study inherent to retrospective data. It was specifically designed to assess differences between two CT scans but did not consider rate of change because we were unable to standardise the timing of CTs. There was no control over the adequacy of inspiration/expiration imaging and although we calculated airway resistances, the lack of standardisation may explain why we did not see significant differences between groups.

Nevertheless, we show for the first time that airway volume can be used to identify CT scans from IPF patients with progressive disease. Several ongoing clinical trials of antifibrotic therapy are focused on progressive fibrotic lung disease in non-IPF disorders [15]; however, it is currently not possible to reliably predict which patients will progress and which will remain stable using baseline data. FRI is a safe, robust mechanism for assessing airway volume and it may be possible that change in siV_{aw} used in conjunction with existing assessment tools is more sensitive to IPF progression than decline in FVC or CT appearances alone. Further evaluation is needed with prospective data in order to answer this question.

Thomas McLellan¹, Peter M. George^{2,3}, Paul Ford⁴, Jan De Backer⁵, Cedric Van Holsbeke⁵, Benjamin Mignot⁵, Nicholas J. Screaton¹, Alessandro Ruggiero¹ and Muhunthan Thillai^{1,6}

¹Royal Papworth Hospital, Cambridge, UK. ²Royal Brompton Hospital, London, UK. ³National Heart and Lung Institute, Imperial College London, London, UK. ⁴Galapagos NV, Mechelen, Belgium. ⁵Fluida NV, Antwerp, Belgium. ⁶Dept of Medicine, University of Cambridge, Cambridge, UK.

Correspondence: Muhunthan Thillai, Interstitial Lung Disease Unit, Royal Papworth Hospital, Biomedical Campus, Cambridge CB2 0AY, UK. E-mail: muhunthan.thillai@nhs.net

Received: 22 Oct 2019 | Accepted after revision: 11 Dec 2019

Acknowledgements: Thanks to Piero Ricchiuto (Cambridge, UK) for assistance with statistical analyses.

Conflict of interest: T. McLellan has received travel support to attend the 2019 ERS International Congress. His salary as a research fellow is paid by Royal Papworth but the grant originally came from Roche. P.M. George reports personal fees and nonfinancial support from Roche and Boehringer Ingelheim, and personal fees from Teva, outside the submitted work. P. Ford is an employee of Galapagos. J. de Backer is an employee of Fluida NV. C. Van Holsbeke is an employee of Fluida NV. B. Mignot is an employee of Fluida NV. N.J. Screaton has nothing to disclose. A. Ruggiero reports a leadership position at Qureight Ltd. Qureight Ltd received financial support from Galapagos N.V. M. Thillai reports a leadership position at Qureight Ltd. Qureight Ltd received financial support from Galapagos NV.

References

- 1 Richeldi L, du Bois RM, Raghu G, *et al.* Efficacy and safety of nintedanib in idiopathic pulmonary fibrosis. *N Engl J Med* 2014; 370: 2071–2082.
- 2 King TE J, Bradford WZ, Castro-Bernardini S, *et al.* A phase 3 trial of pirfenidone in patients with idiopathic pulmonary fibrosis. *N Engl J Med* 2014; 370: 2083–2092.
- 3 Wells AU. Forced vital capacity as a primary end point in idiopathic pulmonary fibrosis treatment trials: making a silk purse from a sow's ear. *Thorax* 2013; 68: 309–310.
- 4 Walsh SLF, Maher TM, Kolb M, *et al.* Diagnostic accuracy of a clinical diagnosis of idiopathic pulmonary fibrosis: an international case-cohort study. *Eur Respir J* 2017; 50: 1700936.
- 5 Jacob J, Bartholmai BJ, van Moorsel CHM, *et al.* Longitudinal prediction of outcome in idiopathic pulmonary fibrosis using automated CT analysis. *Eur Respir J* 2019; 54: 182341.
- 6 Clukers J, Lanclus M, Mignot B, *et al.* Quantitative CT analysis using functional imaging is superior in describing disease progression in idiopathic pulmonary fibrosis compared to forced vital capacity. *Respir Res* 2018; 19: 213.
- 7 Maher TM, van der Aar EM, Van de Steen O, *et al.* Safety, tolerability, pharmacokinetics, and pharmacodynamics of GLPG1690, a novel autotaxin inhibitor, to treat idiopathic pulmonary fibrosis (FLORA): a phase 2a randomised placebo-controlled trial. *Lancet Respir Med* 2018; 6: 627–635.
- 8 Edey AJ, Devaraj AA, Barker RP, *et al.* Fibrotic idiopathic interstitial pneumonias: HRCT findings that predict mortality. *Eur Radiol* 2011; 21: 1586–1593.
- 9 Sumikawa H, Johkoh T, Colby TV, *et al.* Computed tomography findings in pathological usual interstitial pneumonia: relationship to survival. *Am J Respir Crit Care Med* 2008; 177: 433–439.
- 10 Walsh SL, Wells AU, Sverzellati N, *et al.* Relationship between fibroblastic foci profusion and high resolution CT morphology in fibrotic lung disease. *BMC Med* 2015; 13: 241.
- 11 Seibold MA, Smith RW, Urbanek C, *et al.* The idiopathic pulmonary fibrosis honeycomb cyst contains a mucociliary pseudostratified epithelium. *PLoS One* 2013; 8: e58658.
- 12 McDonough JE, Verleden SE, Verschakelen J, *et al.* The structural origin of honeycomb cysts in IPF. *Am J Respir Crit Care Med* 2018; 197: A6388.
- 13 Plantier L, Cazes A, Dinh-Xuan AT, *et al.* Physiology of the lung in idiopathic pulmonary fibrosis. *Eur Respir Rev* 2018; 27: 170062.
- 14 Upagupta C, Shimbori C, Alsilmi R, *et al.* Matrix abnormalities in pulmonary fibrosis. *Eur Respir Rev* 2018; 27: 180033.
- 15 Flaherty KR, Brown KK, Wells AU, *et al.* Design of the PF-ILD trial: a double-blind, randomised, placebo-controlled phase III trial of nintedanib in patients with progressive fibrosing interstitial lung disease. *BMJ Open Respir Res* 2017; 4: e000212.