




Lung ultrasound patterns in paediatric pneumonia in Mozambique and Pakistan

Amy Sarah Ginsburg¹, Pio Vitorino², Zunera Qasim³, Jennifer L. Lenahan⁴, Jun Hwang¹, Alessandro Lamorte⁵, Marta Valente⁶, Benazir Balouch³, Carmen Muñoz Almagro^{7,8,9}, M. Imran Nisar³, Susanne May¹, Fyezah Jehan³, Quique Bassat ^{2,6,7,8,10} and Giovanni Volpicelli¹¹

Affiliations: ¹Dept of Biostatistics, University of Washington, Seattle, WA, USA. ²Centro de Investigação em Saúde de Manhiça (CISM), Maputo, Mozambique. ³Dept of Pediatrics and Child Health, Aga Khan University, Karachi, Pakistan. ⁴Save the Children Federation, Inc., Seattle, WA, USA. ⁵Dept of Emergency Medicine, Parini Hospital, Aosta, Italy. ⁶ISGlobal, Hospital Clínic – Universitat de Barcelona, Barcelona, Spain. ⁷Instituto de Recerca Pediàtrica, Hospital Sant Joan de Déu, Barcelona, Spain. ⁸Consorcio de Investigación Biomédica en Red de Epidemiología y Salud Pública (CIBERESP), Madrid, Spain. ⁹Dept of Medicine, Universitat Internacional de Catalunya, Barcelona, Spain. ¹⁰ICREA, Barcelona, Spain. ¹¹Dept of Emergency Medicine, San Luigi Gonzaga University Hospital, Orbassano, Italy.

Correspondence: Amy Sarah Ginsburg, University of Washington Clinical Trial Center, Building 29, Suite 250, 6200 NE 74th Street, Seattle, WA, 98115, USA. E-mail: messageforamy@gmail.com

ABSTRACT

Objective: Improved pneumonia diagnostics are needed, particularly in resource-constrained settings. Lung ultrasound (LUS) is a promising point-of-care imaging technology for diagnosing pneumonia. The objective was to explore LUS patterns associated with paediatric pneumonia.

Methods: We conducted a prospective, observational study among children aged 2 to 23 months with World Health Organization Integrated Management of Childhood Illness chest-indrawing pneumonia and among children without fast breathing, chest indrawing or fever (no pneumonia cohort) at two district hospitals in Mozambique and Pakistan. We assessed LUS and chest radiograph (CXR) examinations, and viral and bacterial nasopharyngeal carriage, and performed a secondary analysis of LUS patterns.

Results: LUS demonstrated a range of distinctive patterns that differed between children with and without pneumonia and between children in Mozambique *versus* Pakistan. The presence of LUS consolidation or interstitial patterns was more common in children with chest-indrawing pneumonia than in those without pneumonia. Consolidations were also more common among those with only bacterial but no viral carriage detected (50.0%) than among those with both (13.0%) and those with only virus detected (8.3%; $p=0.03$). LUS showed high interrater reliability among expert LUS interpreters for overall determination of pneumonia ($\kappa=0.915$), consolidation ($\kappa=0.915$) and interstitial patterns ($\kappa=0.901$), but interrater reliability between LUS and CXR for detecting consolidations was poor ($\kappa=0.159$, Pakistan) to fair ($\kappa=0.453$, Mozambique).

Discussion: Pattern recognition was discordant between LUS and CXR imaging modalities. Further research is needed to define and standardise LUS patterns associated with paediatric pneumonia and to evaluate the potential value of LUS as a reference standard.



@ERSpublications

This study explored distinctive lung ultrasound patterns associated with paediatric community-acquired pneumonia in Mozambique and Pakistan, and found reliable pattern recognition critical to identifying pneumonia <https://bit.ly/3eWWvXr>

Cite this article as: Ginsburg AS, Vitorino P, Qasim Z, *et al.* Lung ultrasound patterns in paediatric pneumonia in Mozambique and Pakistan. *ERJ Open Res* 2021; 7: 00518-2020 [<https://doi.org/10.1183/23120541.00518-2020>].



This article has been republished to correct an error in the authors' affiliations.

This article has supplementary material available from openres.ersjournals.com

Received: 24 July 2020 | Accepted after revision: 4 Nov 2020 | First published: 1 Feb 2021

Copyright ©ERS 2021. This article is open access and distributed under the terms of the Creative Commons Attribution Non-Commercial Licence 4.0.

Introduction

Pneumonia remains the leading infectious killer of children [1]; effective and timely diagnosis is critical to saving lives. Paediatric pneumonia is difficult to diagnose, especially in resource-constrained settings [2]. Advantages of ultrasound (LUS), a point-of-care tool that can dynamically visualise lungs with promising diagnostic accuracy for pneumonia and greater sensitivity or specificity when compared with chest radiography (CXR), include lower cost, portability, ease-of-use and absence of ionising radiation [3–5]. Key to evaluating the use case of LUS in pneumonia diagnosis in resource-constrained settings is a better understanding of the LUS patterns associated with paediatric pneumonia. We conducted a pilot study in Mozambique and Pakistan to investigate use of LUS for diagnosis and found that among children with World Health Organization (WHO) Integrated Management of Childhood Illness (IMCI) chest-indrawing pneumonia, expert LUS interpreters may achieve substantially higher interrater reliability (IRR) for LUS compared to CXR [6]. We chose to focus on non-severe chest-indrawing pneumonia rather than more severe pneumonia in this study, since we believed it unlikely that LUS imaging would change initial management of severe pneumonia, which is typically treated with intravenous antibiotics. In this secondary analysis, we explore distinctive LUS patterns associated with paediatric pneumonia and potential patterns associated with viral and/or bacterial nasopharyngeal carriage.

Methods

Study design, setting and participants

Methods and primary results of this prospective, observational, facility-based cohort study were described previously [6, 7]. The primary objective was to provide evidence assessing whether the addition of LUS to current pneumonia care pathways improves identification of pneumonia in children presenting to district hospitals in Manhiça, Mozambique and Karachi, Pakistan. Secondary and exploratory objectives included identifying LUS patterns among children with and without chest-indrawing pneumonia and comparing those patterns to CXR patterns. We explored LUS patterns, and available biomarker and viral and bacterial nasopharyngeal carriage results.

Children aged 2 to 23 months meeting WHO IMCI chest-indrawing pneumonia case definition (chest-indrawing pneumonia cohort) in outpatient and/or emergency departments of the low-volume, rural Manhiça District Hospital in Manhiça, Mozambique and the high-volume, urban Sindh Government Children's Hospital–Poverty Eradication Initiative in Karachi, Pakistan were screened sequentially during working hours by study staff to determine eligibility (table 1, figure 1). A separate group of 40 children presenting with complaints of cough or difficulty breathing but without fast breathing, chest indrawing or fever (no pneumonia cohort) was also screened. Conducted in accordance with the International Conference on Harmonisation, Good Clinical Practice and Declaration of Helsinki 2008, the study was approved by the Western Institutional Review Board, Comité Nacional de Bioética para a Saúde (246/CNBS/17), Comité de Ética del Hospital Clínic de Barcelona (HCB/2017/0074) and Aga Khan University Ethics Review Committee, and registered with ClinicalTrials.gov (NCT03187067).

Study procedures

After enrolment on Day 1, eligible children underwent history, physical examination and LUS and CXR examinations. Enrolled children received local standard of care without the results of LUS examinations informing clinical care.

LUS examinations (longitudinal and oblique scans obtained of the anterior, lateral and posterior sides of the chest, figure 2) with a linear probe were performed by four trained non-physician healthcare personnel (nurse and medical agent in Mozambique, and two radiology technicians in Pakistan) who received a 1-day standardised training course and 3-day supervised practice. LUS interpretation using a standardised scoresheet targeted detection of typical lung consolidations, pleural effusions, interstitial patterns and obstructive atelectasis [7, 8]. End-point pneumonia using LUS was defined as the presence of consolidations or pleural effusions. At least two independent physicians expertly trained in LUS interpretation and blinded to clinical presentation interpreted each examination. If discordant, a designated expert LUS interpreter acted as arbiter. LUS operators at each site also interpreted LUS scans independently from one another. All interpretations were performed in batches at a later time using the same standardised scoresheet.

Anteroposterior CXR images were collected based on standard practice at each study site. A CXR interpretation panel of six expert interpreters investigated radiographic indicators of WHO CXR standardised primary end-point pneumonia [9–12]. At least three independent WHO CXR-trained physicians interpreted each CXR. Three interpretations were randomly selected, and if the first two interpretations were discordant, the third would act as tiebreaker.

TABLE 1 Study definitions and eligibility criteria

Definitions	
Fast breathing for age	Children 2 to <12 months of age: RR \geq 50 breaths per min Children \geq 12 months of age: RR \geq 40 breaths per min
Severe respiratory distress	Grunting, nasal flaring and/or head nodding
WHO IMCI general danger signs	Lethargy or unconsciousness, convulsions, vomiting everything, inability to drink or breastfeed
Eligibility criteria	
Inclusion criteria	Chest-indrawing pneumonia cohort 2 to 23 months of age Cough <14 days or difficulty breathing Visible indrawing of the chest wall with or without fast breathing for age Ability and willingness of child's caregiver to provide informed consent and to be available for follow-up for the planned duration of the study, including accepting a home visit if he/she fails to return for a scheduled study follow-up visit
	No pneumonia cohort 2 to 23 months of age Cough <14 days or difficulty breathing Ability and willingness of child's caregiver to provide informed consent and to be available for follow-up for the planned duration of the study, including accepting a home visit if he/she fails to return for a scheduled study follow-up visit
Exclusion criteria	Chest-indrawing pneumonia cohort Resolution of chest indrawing after bronchodilator challenge if wheezing at screening examination Severe respiratory distress Arterial S_{pO_2} <90% in room air, as assessed noninvasively by a pulse oximeter WHO IMCI general danger signs Stridor when calm Known or possible tuberculosis (history of a cough \geq 14 days) Any medical or psychosocial condition or circumstance that, in the opinion of the investigators, would interfere with the conduct of the study or for which study participation might jeopardise the child's health Living outside the study catchment area
	No pneumonia cohort Axillary temperature \geq 38°C Fast breathing for age Visible indrawing of the chest wall S_{pO_2} <95% in room air, as assessed noninvasively by a pulse oximeter WHO IMCI general danger signs Stridor when calm Known or possible tuberculosis (history of a cough \geq 14 days) Any medical or psychosocial condition or circumstance that, in the opinion of the investigators, would interfere with the conduct of the study or for which study participation might jeopardise the child's health Living outside the study catchment area

RR: respiratory rate; WHO: World Health Organization; IMCI: Integrated Management of Childhood Illnesses; S_{pO_2} : oxyhaemoglobin saturation.

Blood samples were tested for haemoglobin and C-reactive protein in Mozambique and Pakistan, and for procalcitonin, malaria and HIV in Mozambique. Nasopharyngeal aspirates and/or swabs were tested for respiratory viral PCR in Mozambique and Pakistan, and bacterial PCR in Mozambique using commercial multiplex tests.

Statistical analysis

Chi-squared tests, Fisher's exact tests, and t-tests were used to compare baseline characteristics of children by country and cohort. Tests were two-sided with $\alpha=0.05$. Multiple comparison adjustments were not made, given the exploratory aims of the analyses. IRR among expert LUS interpreters and among expert CXR interpreters were estimated by cohort using Cohen's kappa (κ). All analyses were performed using R (version 3.5.1; R Foundation for Statistical Computing).

Results

Enrolment began in August 2017 in Mozambique and October 2017 in Pakistan. The last visits were completed in June 2018 in Mozambique and April 2018 in Pakistan. Baseline LUS videos were available for

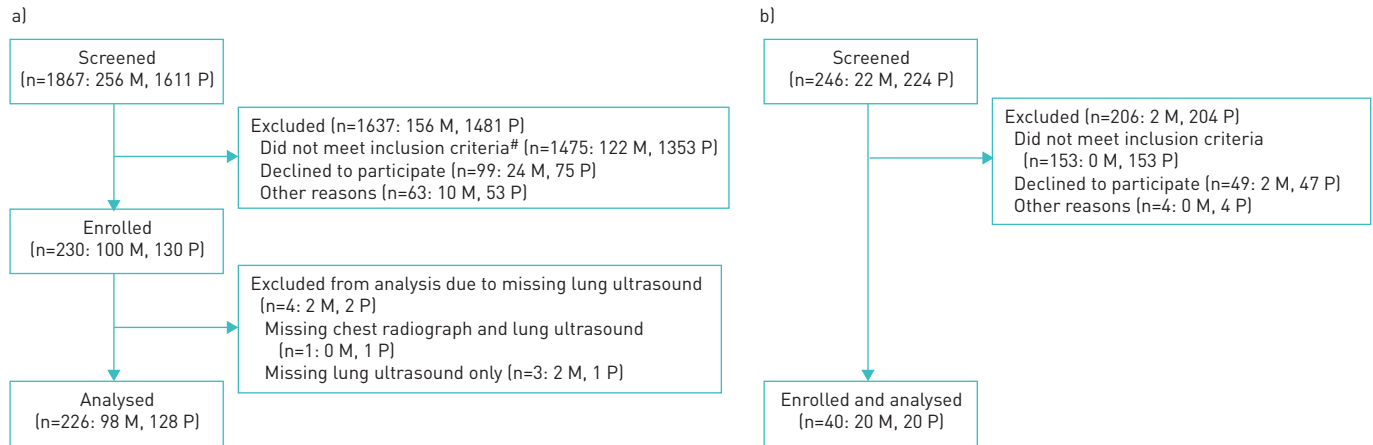


FIGURE 1 a) Flow of children with chest-indrawing pneumonia by country: Mozambique (M) and Pakistan (P). b) Flow of children with no fast breathing, no chest indrawing and no fever by country. #: 70 children in Mozambique (27.3% of screened) and 1318 children in Pakistan (81.8% of screened) met the “no chest indrawing” exclusion criterion.

98 out of 100 and 128 out of 130 children with chest-indrawing pneumonia in Mozambique and Pakistan, respectively (figure 1a), and all 40 in the no pneumonia cohort (figure 1b), with baseline characteristics by cohort and country provided in table 2. One child with an oxyhaemoglobin saturation $<90\%$ was incorrectly enrolled in the chest-indrawing pneumonia cohort in Mozambique. The results reflect the available data from these 226 children in the chest-indrawing pneumonia cohort and 40 children in the no pneumonia cohort. Among children with pneumonia, there were more fevers (21.4% versus 8.6%, $p=0.01$), but less fast breathing (53.1% versus 64.6%, $p=0.10$) in Mozambique than Pakistan. One child had hypoxaemia in Mozambique and none in Pakistan. C-reactive protein measurements were available for 93 and 128 children with pneumonia in Mozambique and Pakistan, respectively, and were on average lower in Mozambique than Pakistan (38.8 versus 109.9 $\mu\text{g}\cdot\text{mL}^{-1}$, $p<0.01$). Among children without pneumonia, C-reactive protein measurements were available in Mozambique, and on average were lower than those among children with pneumonia (18.2 versus 38.8 $\mu\text{g}\cdot\text{mL}^{-1}$, $p=0.03$). Procalcitonin measurements were available for 93 children with pneumonia and 20 children without pneumonia in Mozambique. Average levels were higher in the former group (1.7 $\text{ng}\cdot\text{mL}^{-1}$) than the latter (0.2 $\text{ng}\cdot\text{mL}^{-1}$) ($p=0.07$).

Nasopharyngeal viral carriage results were available for 98 children with pneumonia and 20 children without pneumonia analysed from Mozambique, and 100 children with pneumonia analysed from Pakistan (supplementary appendix 1). Presence of any respiratory virus was similarly high across all tested children in both countries (91.8% Mozambique pneumonia; 84% Pakistan pneumonia; 95% Mozambique no pneumonia). However, the average number of viruses per child was higher among children with pneumonia in Mozambique (1.67) than in Pakistan (1.08; $p<0.01$) or among children without pneumonia in Mozambique (1.25; $p=0.01$).

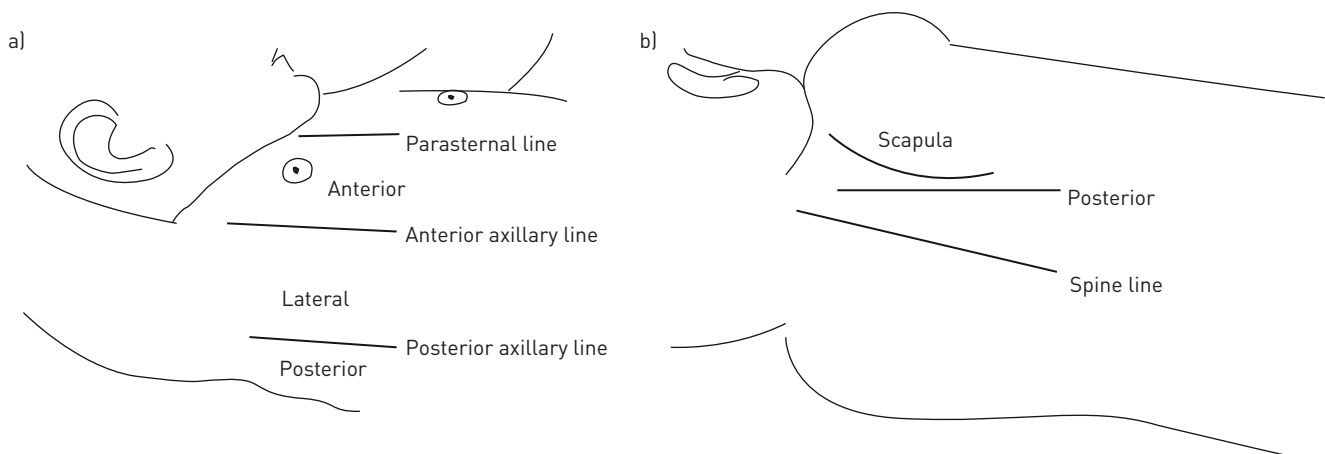


FIGURE 2 Lung ultrasound examinations consisted of longitudinal and oblique scans obtained of the anterior, lateral and posterior sides of the child's chest.

TABLE 2 Baseline characteristics of enrolled and analysed children by cohort and country

	Chest-indrawing pneumonia cohort			No pneumonia cohort			Between-cohort comparison p-value	
	Mozambique	Pakistan	Between-country comparison p-value	Mozambique	Pakistan	Between-country comparison p-value	Mozambique	Pakistan
Subjects n	98	128		20	20			
Age months	10.9±6.0	6.8±4.8	<0.01	11.0±6.1	7.6±4.8	0.06	0.91	0.45
<12 months	55 (56.1%)	111 (86.7%)	<0.01	12 (60.0%)	15 (75.0%)	0.50	0.94	0.18
Female	39 (39.8%)	34 (26.6%)	0.049	14 (70.0%)	12 (60.0%)	0.74	0.03	<0.01
Temperature °C	37.1±1.1	36.7±0.8	<0.01	36.3±0.6	36.3±0.6	0.72	<0.01	0.02
Fever (≥38°C) n (%)	21 (21.4%)	11 (8.6%)	0.01	0 (0.0%)	0 (0.0%)		0.02	0.36
Respiratory rate breaths per min								
<12 months	52.5±11.4	53.5±7.9	0.58	39.7±7.1	38.8±4.8	0.72	<0.01	<0.01
≥12 months	44.3±10.0	47.6±9.6	0.23	34.4±4.2	32.2±4.5	0.41	<0.01	<0.01
Fast breathing	52 (53.1%)	83 (64.8%)	0.10	0 (0.0%)	0 (0.0%)		<0.01	<0.01
Oxyhaemoglobin saturation %	97.8±2.6	95.3±2.2	<0.01	96.2±1.5	96.8±1.6	0.23	<0.01	<0.01
<90% n (%)	1 (1.0%)	0 (0.0%)	0.43	0 (0.0%)	0 (0.0%)		>0.99	
Haemoglobin g·dL⁻¹	10.0±1.3	10.7±1.3	<0.01	10.3±1.0	9.4±1.5	0.04	0.37	<0.01
Positive HIV rapid diagnostic test[#]	0 (0.0%)			0 (0.0%)			>0.99	
Positive malaria rapid diagnostic test[¶]	1 (1.0%)			0 (0.0%)			>0.99	
C-reactive protein[*] µg·mL⁻¹	38.8±49.8	109.9±199.7	<0.01	18.2±33.9			0.03	
Procalcitonin[§] ng·mL⁻¹	1.7±7.2			0.2±0.6			0.07	
<i>Streptococcus pneumoniae</i>^f	84 (86.6%)							
<i>Bordetella pertussis</i>^{###}	3 (3.1%)			0 (0.0%)			>0.99	
<i>Chlamydomphila pneumoniae</i>^{###}	0 (0.0%)			0 (0.0%)				
<i>Legionella pneumophila</i>^{###}	0 (0.0%)			0 (0.0%)				
<i>Mycoplasma pneumoniae</i>^{###}	3 (3.1%)			0 (0.0%)			>0.99	
Nasopharyngeal viral PCR^{¶¶}								
Number of viruses detected	1.67±1.04	1.08±0.65	<0.01	1.25±0.55			0.01	
Any viruses detected	90 (91.8%)	84 (84.0%)	0.14	19 (95.0%)			0.31	
1 virus detected	41 (41.8%)	61 (61.0%)		13 (65.0%)				
2 viruses detected	30 (30.6%)	22 (22.0%)		6 (30.0%)				
≥3 viruses detected	19 (19.4%)	1 (1.0%)		0 (0.0%)				

Data are presented as mean±SD or n (%), unless otherwise stated. [#]: HIV testing only conducted in Mozambique; missing for 55 children with chest-indrawing pneumonia. [¶]: malaria testing only conducted in Mozambique; missing for two children with chest-indrawing pneumonia. ^{*}: C-reactive protein missing for five children with chest-indrawing pneumonia in Mozambique; in Pakistan, only measured for children with chest-indrawing pneumonia. [§]: procalcitonin only measured in Mozambique; missing for five children with chest-indrawing pneumonia. ^f: *S. pneumoniae* carriage only tested for 97 children with chest-indrawing pneumonia in Mozambique. ^{###}: *B. pertussis*, *C. pneumoniae*, *L. pneumophila* and *M. pneumoniae* carriage only tested in Mozambique; all children with *B. pertussis* were also positive for *S. pneumoniae*, and two of the three children with *M. pneumoniae* were also positive for *S. pneumoniae*; no children were positive for both *B. pertussis* and *M. pneumoniae*. ^{¶¶}: viral carriage in Pakistan only tested in 100 analysed children with chest-indrawing pneumonia.

Streptococcus pneumoniae nasopharyngeal carriage results were available for 97 children with pneumonia in Mozambique, while remaining bacterial carriage results were available for all 100 children with pneumonia and 20 children without pneumonia in Mozambique. Most children with pneumonia in Mozambique tested positive for *S. pneumoniae* (86.6%); 3.1% were positive for *Bordetella pertussis* and 3.1% for *Mycoplasma pneumoniae* (table 2). No children without pneumonia were positive for carriage of any of the tested bacterial strains.

Among 97 children with pneumonia in Mozambique for whom both viral and bacterial carriage results were available, eight were positive for at least one bacterial but no viral carriage, 12 were positive for at least one viral but no bacterial carriage and 77 were positive for at least one of both; no children were negative for all tested strains of both (table 3). Among viral-only positives, respiratory syncytial virus (RSV) and rhinovirus were the only strains that appeared without additional viruses in more than one child (three and two, respectively). Among mixed (both viral and bacterial) positives, RSV with *S. pneumoniae* (14 children), rhinovirus with *S. pneumoniae* (eight children) and adenovirus with rhinovirus with *S. pneumoniae* (seven children) were the three most common combinations present. Other combinations were each present in four or fewer children.

LUS patterns

Presence of any LUS consolidation was more common in children with chest-indrawing pneumonia than those without pneumonia (15.3% versus 0.0%, $p=0.07$, Mozambique; 45.5% versus 5.0%, $p<0.01$, Pakistan) as was presence of any LUS interstitial pattern (24.5% versus 10.0%, $p=0.24$, Mozambique; 62.5% versus 30.0%, $p=0.01$, Pakistan, table 4). Neither LUS presence of pleural effusion nor obstructive atelectasis was significantly different between those with and without pneumonia in Mozambique (0.0% throughout) or Pakistan (1.6% versus 0.0%, $p>0.99$; 2.3% versus 0.0%, $p>0.99$, respectively). Among those with pneumonia, LUS consolidation and interstitial patterns were significantly more common in Pakistan than Mozambique ($p<0.01$ for each comparison), though LUS effusion and obstructive atelectasis were not ($p=0.51$; $p=0.26$, respectively). Among those without pneumonia, consolidation and interstitial patterns were not significantly more common in Pakistan than Mozambique ($p>0.99$; $p=0.24$, respectively), and effusion and obstructive atelectasis patterns were absent in all children.

Expert LUS interpreters showed very high levels of IRR in overall determination of pneumonia ($\kappa=0.915$), consolidation ($\kappa=0.915$), effusion ($\kappa=1$) and interstitial patterns ($\kappa=0.901$) among children with pneumonia; estimated IRR was lower, but still moderate to good for obstructive atelectasis ($\kappa=0.746$) (table 5). Of note, the unusual $\kappa=1$ occurred because of very small numbers of children with pleural effusions.

When both expert LUS interpreters determined a given imaging pattern was absent for all children, the κ -value for that imaging pattern was undefined, as was true for children without pneumonia with respect to presence of effusion and obstructive atelectasis. Among children without pneumonia, IRRs for overall pneumonia and for consolidations were estimated to be 1, but these were due to the small number of

TABLE 3 Baseline lung ultrasound pattern by nasopharyngeal carriage in the chest-indrawing pneumonia cohort in Mozambique

	Chest-indrawing pneumonia cohort in Mozambique			
	Bacteria but no viruses detected	Viruses but no bacteria detected	Both bacteria and viruses detected	Carriage type comparison p-value
Subjects n	8	12	77	
Any consolidation	4 (50.0%)	1 (8.3%)	10 (13.0%)	0.03
Peripheral	2 (25.0%)	1 (8.3%)	8 (10.4%)	
Lobar	2 (25.0%)	1 (8.3%)	2 (2.6%)	
Present in both lungs	1 (12.5%)	1 (8.3%)	2 (2.6%)	
Any pleural effusion	0 (0.0%)	0 (0.0%)	0 (0.0%)	
Any interstitial pattern	4 (50.0%)	4 (33.3%)	16 (20.8%)	0.14
Focal	4 (50.0%)	4 (33.3%)	16 (20.8%)	
Multifocal	1 (12.5%)	0 (0.0%)	0 (0.0%)	
Present in both lungs	1 (12.5%)	2 (16.7%)	5 (6.5%)	
Any obstructive atelectasis	0 (0.0%)	0 (0.0%)	0 (0.0%)	

Data are presented as n (%) unless otherwise stated. Both bacterial and viral carriage assessed in Mozambique. Pakistan did not have bacterial carriage testing conducted.

TABLE 4 Baseline lung ultrasound imaging patterns of children by cohort and country

	Chest-indrawing pneumonia cohort			No pneumonia cohort			Between-cohort comparison p-value	
	Mozambique	Pakistan	Between-country comparison p-value	Mozambique	Pakistan	Between-country comparison p-value	Mozambique	Pakistan
Subjects n	98	128		20	20			
Any consolidation	15 (15.3%)	57 (44.5%)	<0.01	0 (0.0%)	1 (5.0%)	>0.99	0.07	<0.01
Peripheral	11 (11.2%)	51 (39.8%)		0 (0.0%)	1 (5.0%)			
Lobar	5 (5.1%)	18 (14.1%)		0 (0.0%)	0 (0.0%)			
Present in both lungs	4 (4.1%)	18 (14.1%)		0 (0.0%)	0 (0.0%)			
Any pleural effusion	0 (0.0%)	2 (1.6%)	0.51	0 (0.0%)	0 (0.0%)			>0.99
Simple	0 (0.0%)	2 (1.6%)		0 (0.0%)	0 (0.0%)			
Complex	0 (0.0%)	0 (0.0%)		0 (0.0%)	0 (0.0%)			
Present in both lungs	0 (0.0%)	0 (0.0%)		0 (0.0%)	0 (0.0%)			
Any interstitial pattern	24 (24.5%)	80 (62.5%)	<0.01	2 (10.0%)	6 (30.0%)	0.24	0.24	0.01
Focal	24 (24.5%)	64 (50.0%)		2 (10.0%)	6 (30.0%)			
Multifocal	1 (1.0%)	28 (21.9%)		0 (0.0%)	1 (5.0%)			
Present in both lungs	8 (8.2%)	46 (35.9%)		0 (0.0%)	4 (20.0%)			
Any obstructive atelectasis	0 (0.0%)	3 (2.3%)	0.26	0 (0.0%)	0 (0.0%)			>0.99
Present in both lungs	0 (0.0%)	0 (0.0%)		0 (0.0%)	0 (0.0%)			

Data are presented as n (%) unless otherwise stated.

children with any findings on LUS. IRR for interstitial patterns was moderate ($\kappa=0.635$), but again, numbers were small.

No additional patterns of differences in LUS results were evident when comparing children with and without viral nasopharyngeal carriage (data not presented). Among children with pneumonia in Mozambique for whom viral and bacterial nasopharyngeal carriage results were available, presence of consolidations differed significantly between bacterial-only, mixed positives and viral-only (50.0% versus 13.0% versus 8.3%, $p=0.03$); other imaging patterns did not (table 3).

CXR patterns

Differences in presence of CXR imaging patterns between cohorts within each country were not significant except for interstitial patterns in Pakistan. CXR interstitial patterns were common in both countries for children with pneumonia (36.1%) and less common among those without pneumonia in Mozambique

TABLE 5 Inter rater reliability among lung ultrasound experts

	Chest-indrawing pneumonia cohort [#] κ	No pneumonia cohort [†] κ
Overall pneumonia	0.915	1 ⁺
Consolidation	0.915	1 ⁺
Pleural effusion	1 ⁺	
Interstitial pattern	0.901	0.635
Obstructive atelectasis	0.746	

Testing of κ only signifies that the level of inter rater reliability differs from what would occur by chance ($\kappa=0$). Thus, p-values are not noted for κ results. [#]: n=226. [†]: n=40. ⁺: based on small counts for one of the two possible categories of inter rater reliability, with two or fewer children in the smaller category.

(15.0%, $p=0.12$) and Pakistan (10.0%, $p=0.04$). Presence of CXR consolidation was more common in Mozambique than Pakistan in both chest-indrawing pneumonia and no pneumonia cohorts (18.6% *versus* 9.8%, $p=0.09$; 20.0% *versus* 0.0%, $p=0.11$, respectively) (supplementary appendix 2). Presence of effusion was detected by CXR in one child with pneumonia in Mozambique (1.0%), while obstructive atelectasis was detected by CXR in one child with pneumonia in Pakistan (0.8%).

Comparison of LUS and CXR patterns

In assessing concordance between expert LUS *versus* expert CXR interpretations regarding presence of consolidation in the chest-indrawing pneumonia cohort, $\kappa=0.453$ for Mozambique and $\kappa=0.159$ for Pakistan; for the no pneumonia cohort, four consolidations were detected by LUS but none by CXR in Mozambique, resulting in $\kappa=0$, and one was detected by CXR but none by LUS in Pakistan, also resulting in $\kappa=0$ (supplementary appendix 3). Regarding presence of effusion in the pneumonia cohort (data not shown), although two were detected by LUS in Pakistan, none were detected by CXR, resulting in $\kappa=0$; likewise, 1 was detected by CXR in Mozambique but none by LUS, also resulting in $\kappa=0$. Corresponding κ -values were undefined for those without pneumonia because no effusions were detected by either modality.

Discussion

In our pilot, LUS demonstrated a range of distinctive patterns that differed between children in the chest-indrawing pneumonia and no pneumonia cohorts and between children in Mozambique *versus* Pakistan. Presence of consolidation or interstitial patterns was more common in children diagnosed with chest-indrawing pneumonia based on WHO IMCI criteria than in those without pneumonia. Presence of pleural effusion or obstructive atelectasis patterns was not significantly different among those children with and without pneumonia, though this was based on small numbers of LUS effusions and obstructive atelectasis. In Pakistan, differences in identification of consolidation and interstitial patterns between those with and without pneumonia were statistically significant. Rates of consolidation and interstitial patterns were significantly higher in Pakistan than Mozambique, possibly due to differences in severity of disease for those eligible and enrolled. Other possible explanations for the different LUS patterns observed among children with chest-indrawing pneumonia include differing epidemiologies of etiological pathogens, presentations of disease, host susceptibility and environmental factors, healthcare-seeking behaviours, and healthcare facility levels (low-volume, rural district hospital in Mozambique and high-volume urban hospital in Pakistan), among others.

Among children with chest-indrawing pneumonia, most children with consolidation also had interstitial patterns in one or both lungs (12 out of 15 (80.0%), Mozambique and 54 out of 57 (94.7%), Pakistan). Of those children with chest-indrawing pneumonia with interstitial patterns, 50% (12 out of 24) in Mozambique and 32.5% (26 out of 80) in Pakistan demonstrated interstitial patterns without consolidation. Thus, children with chest-indrawing pneumonia demonstrate a mix of LUS patterns.

Among children with chest-indrawing pneumonia in Mozambique, consolidations were detected at a higher rate in those with bacterial carriage only (no viral carriage), and more frequently but to a lesser extent among those with mixed bacterial and viral carriage, than among those with viral carriage only. Interstitial patterns were again most frequent among those with bacterial carriage, but least frequent among those with mixed bacterial and viral carriage. One could hypothesise that LUS might be able to assist with etiological detection although in the absence of microbiological diagnosis and confirmation, more research would be necessary. It is not surprising that we find a high percentage of nasopharyngeal carriage in children without pneumonia, but this also implies that these comparisons between carriage and disease are not necessarily indicative of clinical disease status or severity. In a study evaluating LUS use during the 2009 H1N1 influenza A pandemic, investigators defined viral pneumonia as the presence of small subpleural consolidations usually <0.5 cm and/or individual B-lines or confluent B-lines (interstitial pattern), and bacterial pneumonia as the presence of lung consolidation with air bronchograms, and based on 54 observations found that IRR for distinguishing viral from bacterial pneumonia was 0.82 (0.63 to 0.99) [13].

While some variability in LUS pattern findings exists, in our study, LUS appears to be consistent with clinical presentation in identifying consolidation (except for one child in the no pneumonia cohort in Pakistan identified with consolidation on LUS). In the no pneumonia cohort LUS appears to overdiagnose interstitial patterns (eight children) while CXR appears to overdiagnose both consolidation (four children) and interstitial patterns (five children). Abnormal imaging patterns in the absence of clinical disease could lead to overtreatment with antibiotics.

Based on our limited sample, IRR between LUS and CXR was poor in identifying consolidation and pneumonia. Using LUS, it appears there is significantly more disease in Pakistan than Mozambique;

however, using CXR, the opposite seems true (although not significantly). Depending on which imaging modality is used, there is different recognition of disease. The fact that recognition of disease on imaging differs between the study sites by imaging modality may appear paradoxical; however, this may be due to chance or to a lack of an imaging gold standard, making it unclear whether it is LUS or CXR that is performing poorly.

Because study populations and underlying epidemiologies were different between Mozambique and Pakistan, and sample sizes of enrolled children were relatively small at each study site, there were limitations in comparisons that could be made between sites, and between pneumonia and no pneumonia cohorts. Of note, of those screened, 81.8% in Pakistan *versus* 27.3% in Mozambique were not enrolled because they did not have chest indrawing. Possible explanations for this difference could include differences in healthcare-seeking behaviour at the two study sites and/or differences in screening procedures. Importantly, though, great care was undertaken to ensure that all eligibility criteria were met at both study sites. Enrolment in the pneumonia cohort in Mozambique was slower due to smaller presenting numbers than in Pakistan as evidenced by larger differences in those screened *versus* enrolled in Pakistan, and this may have led to sicker children being enrolled in Pakistan (as suggested by higher average C-reactive protein measurement, lower average oxyhaemoglobin saturations, and more LUS consolidation and interstitial patterns in Pakistan).

Additional limitations related to imaging interpretation. For LUS interpretation, detailed expert consensus on what constitutes clinically relevant disease does not exist. While LUS videos were reviewed independently, our expert reviewers were not completely independent because one had been trained by the other. For CXR interpretation methodology, despite being used widely for epidemiological and vaccine effectiveness studies, current WHO CXR interpretation methodology is not intended for clinical use; rather it is intended to serve as a research end-point, and thus, our expert CXR interpretations may miss more subtle disease.

Apart from being difficult to obtain, time-consuming, expensive and exposing its subject to ionising radiation, CXR is also not an ideal reference standard due to its high interrater variability [2–4, 12, 14–19]. In our study, CXR had poor IRR, even among expert CXR interpreters. Pattern recognition was discordant between LUS and CXR imaging modalities. Despite this discordance, LUS imaging may be preferable in identifying patterns; however, further research is needed to define and standardise LUS patterns associated with paediatric pneumonia. In addition, while more data may be needed to support LUS as a reference standard, in favour of LUS as a preferred imaging modality for paediatric pneumonia is its high IRR among expert LUS interpreters for overall determination of pneumonia, consolidation and interstitial patterns. LUS pattern recognition and image analysis is a potential tool to allow machine-learning and artificial intelligence-assisted automatic diagnosis of pneumonia. More research is needed to define and standardise LUS patterns associated with paediatric pneumonia and to evaluate the potential value of LUS as a reference standard.

Acknowledgments: We thank the dedicated study staff at Manhiça District Hospital in Manhiça, Mozambique and Sindh Government Children's Hospital–Poverty Eradication Initiative in Karachi, Pakistan for implementing the study and providing patient care. We thank Adelina Malembe and Zumilda Araújo Boca in Mozambique and Fariha Sohail and Zunera Qasim in Pakistan for conducting and interpreting the lung ultrasound (LUS) examinations. We thank Campos Mucasse and Vania Afuale in Mozambique and Farrukh Abbasi, Zehra Aziz, Ghazala Sheikh, and Naveed Ahmad in Pakistan for general coordination and support of the study. We also thank the trial participants, their caregivers, and the local community in Manhiça, Mozambique and Karachi, Pakistan for their participation and support. In addition, we acknowledge Nick Fancourt and Steve Lacey for their technical guidance in the CXR portion of the study, and the expert panel of CXR interpreters (Rachel Benamore, Vera Manduku, Eric McCollum, Kate Park, Joyce Sande and Pui-Ying Iroh Tam) as well as Angelo Giovanni Del Monaco for providing LUS arbitration. We acknowledge Lillian Ambrogio for her guidance in developing the standardised LUS and chest radiography forms.

This study is registered at www.ClinicalTrials.gov with identifier number NCT03187067. Upon request, deidentified participant data that underlie the results reported in this article will be made available to researchers who provide a methodologically sound proposal following publication of the planned primary and secondary analyses. Proposals should be directed to the corresponding author.

Author contributions: A.S. Ginsburg conceptualised the study, obtained research funding, designed the study and data collection instruments, coordinated and supervised data collection from the sites, interpreted the data, and drafted the manuscript. J. Lenahan designed the study and data collection instruments, and coordinated and supervised data collection from the sites. A. Lamorte and G. Volpicelli provided input on the design of the study and designed the lung ultrasound methodology. F. Jehan and Q. Bassat provided input on the design of the study and supervised teams that acquired the data. Among the authors, P. Vitorino, M. Valente, B. Balouch, M.I. Nisar and Z. Qasim conducted the clinical procedures and acquired the data. J. Hwang and S. May performed the statistical analyses and interpreted the data, and drafted sections of the manuscript. C. Muñoz Almagro conducted laboratory analyses from Mozambique. All authors worked collaboratively to review and revise the manuscript and agree to be accountable for the work.

Conflict of interest: A.S. Ginsburg reports grants from the Bill and Melinda Gates Foundation during the conduct of the study. P. Vitorino has nothing to disclose. Z. Qasim has nothing to disclose. J.L. Lenahan has nothing to disclose. J. Hwang has nothing to disclose. A. Lamorte has nothing to disclose. M. Valente has nothing to disclose. B. Balouch has nothing to disclose. C. Muñoz Almagro has nothing to disclose. M.I. Nisar has nothing to disclose. S. May reports grants from the Bill and Melinda Gates Foundation during the conduct of the study. F. Jehan has nothing to disclose. Q. Bassat has nothing to disclose. G. Volpicelli has nothing to disclose.

Support statement: This work was supported by grants from the Bill and Melinda Gates Foundation (OPP1105080) and Save the Children. Hosting of lung ultrasound and chest radiography interpretation data *via* REDCAP at The Institute of Translational Health Sciences was supported by a grant from the National Institutes of Health National Center for Advancing Translational Sciences (UL1 TR002319). CISM is supported by the Government of Mozambique and the Spanish Agency for International Development. ISGlobal receives support from the Spanish Ministry of Science and Innovation through the “Centro de Excelencia Severo Ochoa 2019–2023” Program (CEX2018-000806-S), and support from the Generalitat de Catalunya through the CERCA Program. Funding information for this article has been deposited with theCrossref Funder Registry.

References

- 1 Liu L, Oza S, Hogan D, *et al.* Global, regional, and national causes of child mortality in 2000–13, with projections to inform post-2015 priorities: an updated systematic analysis. *Lancet* 2015; 385: 430–440.
- 2 Mackenzie G. The definition and classification of pneumonia. *Pneumonia (Nathan)* 2016; 8: 14.
- 3 Pereda MA, Chavez MA, Hooper-Miele CC, *et al.* Lung ultrasound for the diagnosis of pneumonia in children: a meta-analysis. *Pediatrics* 2015; 135: 714–722.
- 4 Stadler JAM, Andronikou S, Zar HJ. Lung ultrasound for the diagnosis of community-acquired pneumonia in children. *Pediatr Radiol* 2017; 47: 1412–1419.
- 5 Xin H, Li J, Hu HY. Is lung ultrasound useful for diagnosing pneumonia in children? A meta-analysis and systematic review. *Ultrasound Q* 2018; 34: 3–10.
- 6 Ginsburg AS, Lenahan JL, Jehan F, *et al.* Performance of lung ultrasound in the diagnosis of pediatric pneumonia in Mozambique and Pakistan. *Pediatr Pulmonol* 2020; in press [https://doi.org/10.1002/ppul.25176].
- 7 Lenahan JL, Volpicelli G, Lamorte A, *et al.* Multicentre pilot study evaluation of lung ultrasound for the management of paediatric pneumonia in low-resource settings: a study protocol. *BMJ Open Respir Res* 2018; 5: e000340.
- 8 Volpicelli G, Elbarbary M, Blaivas M, *et al.* International evidence-based recommendations for point-of-care lung ultrasound. *Intensive Care Med* 2012; 38: 577–591.
- 9 Ambroggio L, Sucharew H, Rattan MS, *et al.* Lung ultrasonography: a viable alternative to chest radiography in children with suspected pneumonia? *J Pediatr* 2016; 176: 93–98.
- 10 Cherian T, Mulholland EK, Carlin JB, *et al.* Standardized interpretation of paediatric chest radiographs for the diagnosis of pneumonia in epidemiological studies. *Bull World Health Organ* 2005; 83: 353–359.
- 11 Mahomed N, Fancourt N, de Campo J, *et al.* Preliminary report from the World Health Organisation Chest Radiography in Epidemiological Studies project. *Pediatr Radiol* 2017; 47: 1399–1404.
- 12 Fancourt N, Deloria Knoll M, Barger-Kamate B, *et al.* Standardized interpretation of chest radiographs in cases of pediatric pneumonia from the PERCH Study. *Clin Infect Dis* 2017; 64: Suppl. 3, S253–S261.
- 13 Tsung JW, Kessler DO, Shah VP. Prospective application of clinician-performed lung ultrasonography during the 2009 H1N1 influenza A pandemic: distinguishing viral from bacterial pneumonia. *Crit Ultrasound J* 2012; 4: 16.
- 14 Hayden GE, Wrenn KW. Chest radiograph vs. computed tomography scan in the evaluation for pneumonia. *J Emerg Med* 2009; 36: 266–270.
- 15 Upchurch CP, Grijalva CG, Wunderink RG, *et al.* Community-acquired pneumonia visualized on CT scans but not chest radiographs: pathogens, severity, and clinical outcomes. *Chest* 2018; 153: 601–610.
- 16 Balk DS, Lee C, Schafer J, *et al.* Lung ultrasound compared to chest X-ray for diagnosis of pediatric pneumonia: a meta-analysis. *Pediatr Pulmonol* 2018; 53: 1130–1139.
- 17 Makhnevich A, Sinvani L, Cohen SL, *et al.* The clinical utility of chest radiography for identifying pneumonia: accounting for diagnostic uncertainty in radiology reports. *AJR Am J Roentgenol* 2019; 213: 1207–1212.
- 18 Williams GJ, Macaskill P, Kerr M, *et al.* Variability and accuracy in interpretation of consolidation on chest radiography for diagnosing pneumonia in children under 5 years of age. *Pediatr Pulmonol* 2013; 48: 1195–1200.
- 19 Self WH, Courtney DM, McNaughton CD, *et al.* High discordance of chest x-ray and computed tomography for detection of pulmonary opacities in ED patients: implications for diagnosing pneumonia. *Am J Emerg Med* 2013; 31: 401–405.