



Early View

Research letter

Mammomonogamus laryngeus: an unusual cause of acute and chronic cough in Caribbean area

Moustapha Agossou, Sandy Jean-Baptiste, Ninon Ehret, Nicole Desbois-Nogard, Moustapha Drame, Nicolas Venissac

Please cite this article as: Agossou M, Jean-Baptiste S, Ehret N, *et al.* Mammomonogamus laryngeus: an unusual cause of acute and chronic cough in Caribbean area. *ERJ Open Res* 2021; in press (<https://doi.org/10.1183/23120541.00814-2020>).

This manuscript has recently been accepted for publication in the *ERJ Open Research*. It is published here in its accepted form prior to copyediting and typesetting by our production team. After these production processes are complete and the authors have approved the resulting proofs, the article will move to the latest issue of the ERJOR online.

Copyright ©ERS 2021. This article is open access and distributed under the terms of the Creative Commons Attribution Non-Commercial Licence 4.0.

Mammomonogamus laryngeus: an unusual cause of acute and chronic cough in Caribbean area

Moustapha AGOSSOU^a, Sandy JEAN-BAPTISTE^a, Ninon EHRET^a, Nicole DESBOIS-NOGARD^b, Moustapha DRAME^c, Nicolas VENISSAC^d

^a Department of Respiratory care, CHU Martinique

^b Parasitology-Mycolology Laboratory, CHU Martinique

^c Department of clinical research and Innovation, CHU Martinique

^d Department of Thoracic Surgery, CHRU Lille

Corresponding author:

Moustapha AGOSSOU

Department of Respiratory care, CHU Martinique

Route de Chateauboeuf

97261 Fort-de-France, CEDEX

Email: moustapha.agossou@chu-martinique.fr

Mammomonogamus : an unusual cause of cough in Caribbean area

Abstract:

Mammomonogamosis is a parasitosis caused by a nematode of the genus Mammomonogamus. This parasitosis persists in certain tropical areas, particularly the Caribbean, despite the improvement in the living conditions of the populations. The main symptomatology is cough, which may be accompanied by some general signs and hypereosinophilia. The worms are found in the course of bronchial endoscopy. Patients receive antiparasitic treatment after the extraction.

This parasitosis can infect tourists who are frequent in the region.

It is important not to ignore such a diagnostic hypothesis when faced with an unexplained cough in a person who has stayed in an endemic area.

Introduction

Mammomonogamus or Syngamus is a nematode in the family of the Syngamidae. It is most often found in tropical environments. The parasite infests the respiratory tract of some animals such as cattle, goats, and sheeps. Human infestation is rare. Mammomonogamus parasitizes the respiratory tract and is responsible for respiratory symptoms dominated by coughing (1). A hundred cases have been described in the literature, nearly half of which came from the Caribbean (1–3). In Martinique, the description of the parasite was made in the 1950s and the largest series was published there (2,3). Despite the improvement in lifestyle since the 1980s, human infestation by Mammomonogamus persists in Martinique.

The objective of this study is to describe the clinical, biological and radiological characteristics of patients with mammomonogamosis

Patients and methods

This is a retrospective and descriptive study.

Cases of mammomonogamosis were identified between the 1st January 2008 and August 31, 2020, from the Pneumology department of the Martinique teaching hospitals. These were patients who underwent bronchial fibroscopy and in whom endobronchial mammomonogamus laryngeus larvae were found (Figure 1).

Patients usually have a consultation with a pneumologist before performing the exam.

Data collection concerned age, sex, reason for consultation, biological abnormalities, radiological abnormalities, treatment, and patient's evolution.

Subject provided consent for the image to be used for publication purposes.

Results

During the period of 1st January 2008 to August 31, 2020, 12 patients were diagnosed with mammomonogamiasis at the Teaching Hospital Martinique. Among them 10 were women. The average age of the patients was 36 +/- 13 years. Cough was the characteristic symptom in all cases, and mainly dry cough. In one case, the cough was accompanied by haemoptysis. The duration of symptoms before diagnosis varied from 10 days to more than 6 months. In addition to coughing, one patient presented digestive disorders such as vomiting, and weight loss (loss of 10%). Another patient presented a long-term febrile condition.

On thoracic imaging, three patients presented pulmonary infiltrate-type abnormalities. Imaging was normal in the other cases.

Biologically, two patients presented blood hypereosinophilia : 1,04 G/L (9,2%) and 0,76 G/L (8,5%). Over ten patients had eosinophilia under 0,5 G/L.

The worms were detected during bronchial endoscopy. It is usually a pair of worms intertwined. It was removed with the forceps 1 to 4 pairs.

The patients then benefited from an antiparasitic treatment, either with Albendazole 400 mg per day for 10 days or by Ivermectin according to the weight in a renewed dose 15 days later. The evolution is often marked by the disappearance of symptoms from the third day of treatment. None of the patients relapsed.

Discussion

Mammomonogamiasis is a parasitosis found in tropical areas. It most often affects animals such as cattle, goats, sheeps, or felines. Human involvement is rare but persists in some areas. About a hundred cases have been described in the literature,

most of which came from the Caribbean and Latin America. (1,4,5). But cases have also been described in Asia (6,7).

This parasitosis persists in Martinique where the largest series has been described by Mornex and al. In the 1980's (2), despite the improvement in the living conditions of the populations.

In our context, mammomonogamosis mainly affects women, who are rather young. This gender difference is not found in the literature. We have no explanation to date for this female predominance other than sampling fluctuation.

The main symptom remains a dry irritant cough with usually normal imaging (1,8–10). But chest CT-scan can show abnormalities type frosted glass or condensations on the lung.

The endoscopy makes it possible to highlight worms of mammomonogamus laryngeus (Figure 1).

While nearly half of the cases have been described in Martinique, mammomonogamosis also concerns tourists and many cases have been diagnosed after returning to their country of origin. (1,11). This unusual situation can lead to underdiagnosis.

Conclusion

Mammomonogamosis is a parasitic disease that persists in tropical areas and can infect humans. The main symptomatology associated with lung involvement is a dry cough. Mammomogamus can infect tourists.

The Caribbean is an important tourist area and it is a diagnosis that must imperatively be evoked in the face of a chronic misunderstood cough in a patient returning from an endemic area.

References

1. Nosanchuk JS, Wade SE, Landolf M. Case report of and description of parasite in *Mammomonogamus laryngeus* (human syngamosis) infection. *J Clin Microbiol.* avr 1995;33(4):998-1000.
2. Saint-Prix L. [Human syngamosis in Martinique]. *Ann Parasitol Hum Comp.* 1950;25(3):235-6.
3. Mornex JF, Magdeleine J, De Thore J. [Human *Syngamus* (*Mammomonogonus nasicola*) infestation as a cause of chronic cough in Martinique. 37 cases (author's transl)]. *Nouv Presse Med.* 13 déc 1980;9(47):3628.
4. Castaño JC, Núñez FA, González MM, Téllez G, Giraldo MI. [First case report of *Mammomonogamus* (*Syngamus*) *laryngeus* human infection in Colombia]. *Biomed Rev Inst Nac Salud.* sept 2006;26(3):337-41.
5. Marques SMT, Quadros RM, Pilati C. *Mammomonogamus laryngeus* (Railliet, 1899) infection in buffaloes in Rio Grande do Sul, Brazil. *Vet Parasitol.* 30 juin 2005;130(3-4):241-3.
6. Van Aken D, Lagapa JT, Dargantes AP, Vercruysse J. *Mammomonogamus laryngeus* (Railliet, 1899) infections in cattle in Mindanao, Philippines. *Vet Parasitol.* 16 sept 1996;64(4):329-32.
7. Foitová I, Koubková B, Barus V, Nurcahyo W. Presence and species identification of the gapeworm *Mammomonogamus laryngeus* (Railliet, 1899)

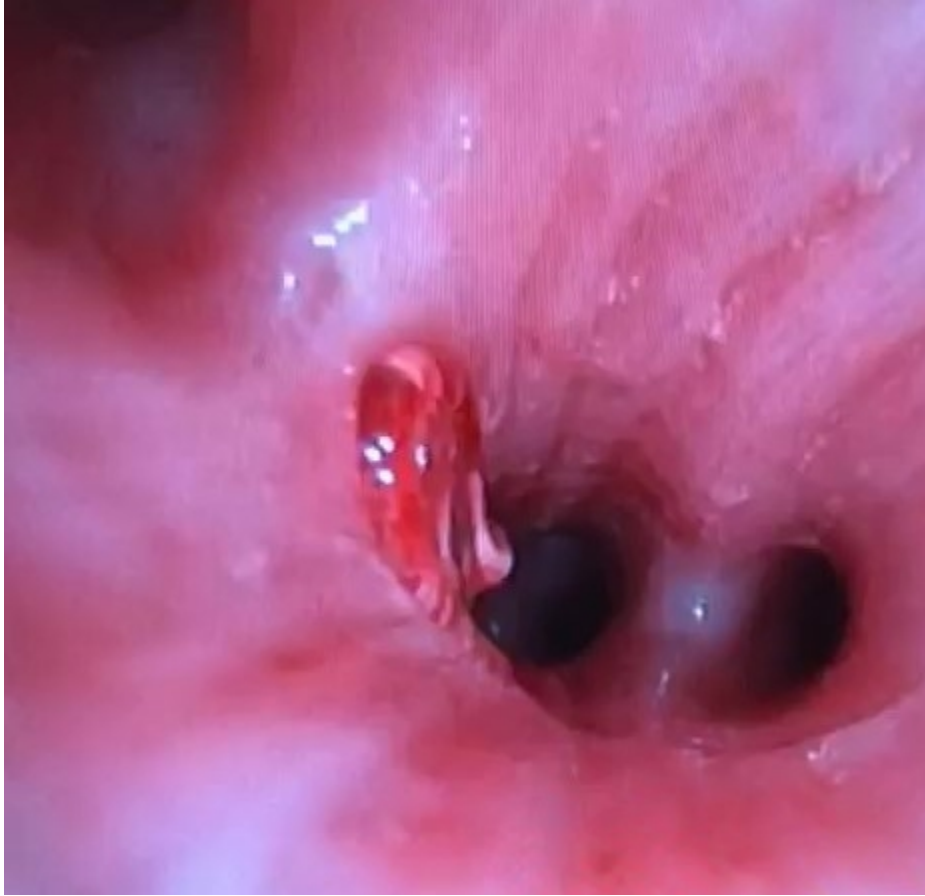
(Syngamidae: Nematoda) in a semi-wild population of Sumatran orangutan (*Pongo abelii*) in Indonesia. *Res Vet Sci.* avr 2008;84(2):232-6.

8. Pontes PA, Gadelha ME, Gregorio LC. Pathologic quiz case 2. Laryngeal syngamosis. *Arch Otolaryngol Head Neck Surg.* mai 1993;119(5):570-1, 573-4.

9. Gardiner CH, Schantz PM. *Mammomonogamus* infection in a human. Report of a case. *Am J Trop Med Hyg.* sept 1983;32(5):995-7.

10. Timmons RF, Bowers RE, Price DL. Infection of the respiratory tract with *Mammomanogamus* (*Syngamus*) *laryngeus*: a new case in Largo, Florida, and a summary of previously reported cases. *Am Rev Respir Dis.* sept 1983;128(3):566-9.

11. Angheben A, Gobbo M, Gobbi F, Bravin A, Toneatti F, Crismancich F, et al. Human syngamosis: an unusual cause of chronic cough in travellers. *BMJ Case Rep.* 2009;2009.



Mammomonogamus worm in the bronchus