



Lung involvement during the prediagnostic phase of idiopathic pleuroparenchymal fibroelastosis

Copyright ©The authors 2022

This version is distributed under the terms of the Creative Commons Attribution Non-Commercial Licence 4.0. For commercial reproduction rights and permissions contact permissions@ersnet.org

Received: 9 Sept 2021
Accepted: 28 Dec 2021

To the Editor:

Idiopathic pleuroparenchymal fibroelastosis (IPPFE) is a rare interstitial pneumonia that predominantly affects the upper lung fields [1, 2]. A pulmonary apical cap (PAC) is an imaging finding resembling that for PPFE that does not show symptoms or progression [3, 4]. Some patients with PPFE have recognised lung involvement at the lung apex long before the diagnosis is actually made, findings that are indistinguishable from PAC based on temporal imaging data [5]. Clinically, it takes months to years from the first recognition of lung involvement to the diagnosis of PPFE [6, 7]. However, no study has yet focused on the progression of lung involvement or the clinical course before the diagnosis of IPPFE. The present study evaluated the prediagnostic clinical course in patients with IPPFE.

The Fukuoka University Chikushi Hospital Institutional Review Board approved the study protocol and waived the requirement for informed consent (approval number: C20-09-002). We examined consecutive patients who were diagnosed with IPPFE at Fukuoka University Chikushi Hospital from January 2010 to December 2020. We extracted patients who had had chest images collected for follow-up of lung involvement or other diseases or who had undergone medical check-ups over a period of more than five years before the diagnosis of IPPFE. We reevaluated the patients to confirm the diagnosis according to the diagnostic criteria of IPPFE [7]. We extracted the first day that patients complained about the symptoms, the date of the diagnosis, and the last day of observation (death or last survival follow-up) from the medical records. The date of the diagnosis was set as the date at which PPFE was first described as the diagnosis in the medical record. We defined apical fibrosis as linear or curved density at the lung apex on chest radiography or subpleural wedge-shaped consolidation at the lung apex on chest computed tomography [8, 9]. Two experienced pulmonary physicians (T.M. and Y.K.) evaluated all chest radiography and computed tomography images collected before the diagnosis. The date of the first recognition of apical fibrosis was defined as the date on which either investigator first recognised apical fibrosis, and the deterioration date was defined as the date on which both investigators decided that apical fibrosis had worsened beyond the date of first recognition. Continuous data are shown as the group median (interquartile range), and categorical data are shown as the number (percentage).

A total of 49 patients were diagnosed with IPPFE during the period, and 20 patients were eligible for this study. The clinical characteristics of the enrolled patients were as follows: 15 men and 5 women; 74 (71–78) years old; body mass index of 18.9 (17.1–20.0) kg·m⁻²; forced vital capacity of 2115 (1580–2430) mL (68.2% (50.2%–84.7%)); and residual volume/total lung capacity of 0.48 (0.41–0.50) (119% (107%–131%)). Ten of the 20 patients (50%) were complicated with interstitial pneumonia other than PPFE in the lower lobes. The period from the oldest radiographic examination to the diagnosis was 7.82 (5.80–12.9) years. The mean frequency of radiological examinations before the diagnosis per patient was 1.59 times per year: 0.90 (0.53–1.41) times per year for chest radiography and 0.59 (0.27–0.74) times per year for chest CT. The period from the first recognition of apical fibrosis to the last observation was 6.71 (6.14–9.98) years, consisting of 5.94 (5.40–7.35) years from the first recognition of apical fibrosis to the diagnosis and 0.93 (0.57–1.42) years from the diagnosis to the last observation. The percentage of the time from the diagnosis to the last observation against the time from the first recognition of apical fibrosis to the last observation was calculated to be 13.8% (0.93/6.71 years). The period from the first recognition of apical fibrosis to the deterioration was 5.38 (1.86–6.39) years. Eleven of the 20 patients (55%) had apical fibrosis that had not



Shareable abstract (@ERSpublications)

Patients with PPFE sometimes have lung involvement at the lung apex long before the diagnosis. The prediagnostic phase with apical fibrosis is much longer than the postdiagnostic phase in patients with PPFE. <https://bit.ly/32X1iXi>

Cite this article as: Miyamura T, Kinoshita Y, Kushima H, et al. Lung involvement during the prediagnostic phase of idiopathic pleuroparenchymal fibroelastosis. *ERJ Open Res* 2022; 8: 00548-2021 [DOI: 10.1183/23120541.00548-2021].

progressed for more than 5 years before the diagnosis. The period from the symptoms to the diagnosis was 1.66 (0.86–3.61) years. The results for each patient are shown in figure 1.

The early stage of PPFE is sometimes indistinguishable from PAC based on temporal imaging data [7]. Differentiating the two entities requires a retrospective review or prospective follow-up of the imaging data [3, 5, 7]. In this study, the period from the first recognition of apical fibrosis to the deterioration was 5.38 (1.86–6.39) years, suggesting the difficulty in differentiating PPFE from PAC by a short-term observation. PAC is a relatively common imaging finding. RENNER *et al.* [8] identified a unilateral PAC in 11.2% and a bilateral PAC in 10.9% by routine chest radiography. Therefore, from a cost-effectiveness perspective, it might be wasteful to follow all patients with lung involvement at the lung apex. However, we should carefully examine the lung involvement of patients with apical fibrosis over a relatively long period, as the prediagnostic phase of PPFE is indistinguishable from PAC by short-term observation. PPFE should be at least considered when patients with apical fibrosis complain of respiratory symptoms during the course of the disease.

MARINESCU *et al.* [10] recently described a patient with PAC that evolved into PPFE after lung surgery and speculated that the presence of PAC predisposes patients to PPFE development when faced with ongoing inflammatory injury. Although the insults were unidentified in patients with IPPFE and whether this apical fibrosis should be recognised as PAC or an early phase of PPFE was an intrinsic problem, we showed that half of the patients with IPPFE had apical fibrosis that did not progress long before the diagnosis. The idea that PAC is a risk factor for PPFE may apply not only to post-operative PPFE but also to IPPFE. It may be necessary to recognise PAC and PPFE as part of the same spectrum rather than as separate concepts, as their pathology shares the common finding of subpleural fibroelastosis, aside from the

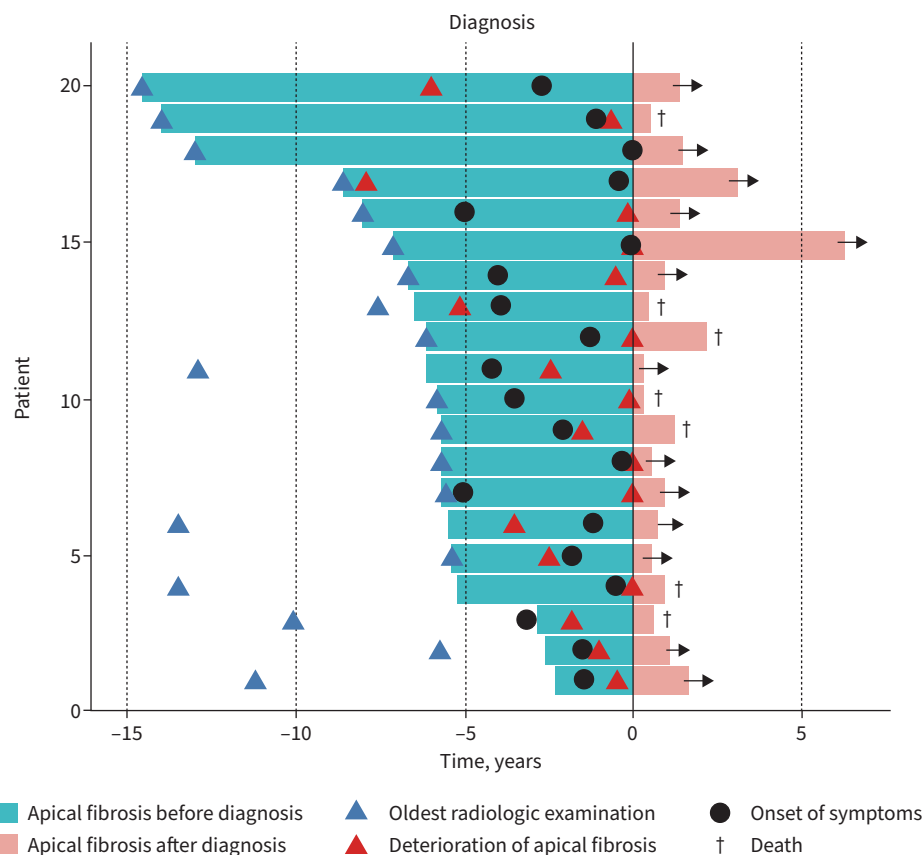


FIGURE 1 The results of the radiological assessment and clinical course in 20 patients with idiopathic pleuroparenchymal fibroelastosis. The green bar indicates the period for which apical fibrosis was detected before the diagnosis of idiopathic pleuroparenchymal fibroelastosis. The mean period (interquartile range) from the first recognition of apical fibrosis to the deterioration (from the left end of the green bar to the red triangle) was 5.38 (1.86–6.39) years.

extent of the lesion [3, 9]. Of note, EGASHIRA *et al.* [11] showed that the risk factors for progression of apical fibrosis in patients with apical fibrosis detected on daily computed tomography was a horizontal extent of apical fibrosis (proportion of lesion to the whole circumference at the most affected section) exceeding 25%. Therefore, patients with extensive apical fibrosis might need to be radiologically followed for short-term observation. The prognosis after the diagnosis of IPPFE is poor, with 5-year survival rates of 23.3%–58.9% [12–16]. The percentage of the time from the diagnosis to the last observation in the time from the first recognition of fibrosis to the last observation was 13.8%. Therefore, if the clinical course of PPFE is perceived as the entire period with apical fibrosis, the duration of undiagnosed IPPFE in the presence of apical fibrosis may be much longer than the clinical course after the diagnosis.

In this study, 10 of the 20 patients were complicated with interstitial pneumonia other than PPFE in the lower lobes. The lower lobe lesions in these patients were radiologically classified as usual interstitial pneumonia (UIP) (n=4), probable UIP (n=3) or unclassifiable interstitial pneumonia (n=3), according to the official American Thoracic Society, European Respiratory Society, Japanese Respiratory Society, and Latin American Thoracic Society clinical practice guidelines of 2018 [17].

We believe that different pathologic processes are at work in the upper and lower lobes, as the pathology differs between PPFE and UIP. We previously suggested that UIP lesions in the lower lobes and PPFE lesions in the upper lobes might both be formed by abnormal healing processes caused by stimuli such as acute lung injury and inflammation, but the eventual pattern of abnormal healing may differ in the upper and lower lobes. In other words, interstitial inflammation and fibrosis as the initial stage might progress to honeycomb lung as end-stage fibrosis in the lower lobes of PPFE patients but be replaced by subpleural fibroelastosis in the upper lobes of PPFE patients [18]. Several limitations associated with the present study warrant mention. First, the timing of the diagnosis may vary, depending on whether or not the clinician is familiar with the diagnosis of PPFE. Second, there were 11 cases (55%) in which apical fibrosis was already present at the initial radiological examination, suggesting that the period from the appearance of apical fibrosis to the diagnosis is longer in these cases. Given the absence of a control group of patients with PAC, it is impossible to suggest follow-up for all patients with PAC. In addition to the small sample size of the study, there were some cases in which the prognosis was not yet determined. In such cases, the observation period after diagnosis will be longer.

Patients with IPPFE sometimes have lung involvement at the lung apex long before the diagnosis. The prediagnostic phase with apical fibrosis was much longer than the postdiagnostic phase in patients with IPPFE. The prediagnostic phase of PPFE is indistinguishable from PAC on short-term observation.

Takuto Miyamura^{1,3}, Yoshiaki Kinoshita^{1,3}, Hisako Kushima¹, Hiroshi Mukae² and Hiroshi Ishii ¹

¹Dept of Respiratory Medicine, Fukuoka University Chikushi Hospital, Fukuoka, Japan. ²Dept of Respiratory Medicine, Nagasaki University Graduate School of Biomedical Sciences, Nagasaki, Japan. ³These authors contributed equally.

Corresponding author: Hiroshi Ishii (hishii@fukuoka-u.ac.jp)

Provenance: Submitted article, peer reviewed.

Conflict of interest: T. Miyamura has nothing to disclose. Y. Kinoshita has nothing to disclose. H. Kushima has nothing to disclose. H. Mukae has nothing to disclose. H. Ishii has nothing to disclose.

Support statement: This study was supported by Japan Society for the Promotion of Science grant JP21K16153. Funding information for this article has been deposited with the Crossref Funder Registry.

References

- 1 Frankel SK, Cool CD, Lynch DA, *et al.* Idiopathic pleuroparenchymal fibroelastosis: description of a novel clinicopathologic entity. *Chest* 2004; 126: 2007–2013.
- 2 Travis WD, Costabel U, Hansell DM, *et al.* An official American Thoracic Society/European Respiratory Society statement: update of the international multidisciplinary classification of the idiopathic interstitial pneumonias. *Am J Respir Crit Care Med* 2013; 188: 733–748.
- 3 Kinoshita Y, Ishii H, Nabeshima K, *et al.* The pathogenesis and pathology of idiopathic pleuroparenchymal fibroelastosis. *Histol Histopathol* 2021; 36: 291–303.

- 4 Lagstein A. Pulmonary apical cap-what's old is new again. *Arch Pathol Lab Med* 2015; 139: 1258–1262.
- 5 Watanabe K, Nagata N, Kitasato Y, et al. Rapid decrease in forced vital capacity in patients with idiopathic pulmonary upper lobe fibrosis. *Respir Investig* 2012; 50: 88–97.
- 6 Ricoy J, Suárez-Antelo J, Antúnez J, et al. Pleuroparenchymal fibroelastosis: clinical, radiological and histopathological features. *Respir Med* 2021; 4: 106437.
- 7 Watanabe K, Ishii H, Kiyomi F, et al. Criteria for the diagnosis of idiopathic pleuroparenchymal fibroelastosis: a proposal. *Respir Investig* 2019; 57: 312–320.
- 8 Renner RR, Markarian B, Pernice NJ, et al. The apical cap. *Radiology* 1974; 110: 569–573.
- 9 Yousem SA. Pulmonary apical cap: a distinctive but poorly recognized lesion in pulmonary surgical pathology. *Am J Surg Pathol* 2001; 25: 679–683.
- 10 Marinescu DC, English J, Sedlic T, et al. Pulmonary apical cap as a potential risk factor for pleuroparenchymal fibroelastosis. *Chest* 2021; 159: e365–e370.
- 11 Egashira R, Yamaguchi K, Kondo T, et al. Pleuroparenchymal fibroelastosis (PPFE)-like finding on CT in daily practice -prevalence and serial changes. *Eur J Radiol Open* 2020; 7: 100296.
- 12 Enomoto Y, Nakamura Y, Satake Y, et al. Clinical diagnosis of idiopathic pleuroparenchymal fibroelastosis: a retrospective multicenter study. *Respir Med* 2017; 133: 1–5.
- 13 Fujisawa T, Mori K, Mikamo M, et al. Nationwide cloud-based integrated database of idiopathic interstitial pneumonias for multidisciplinary discussion. *Eur Respir J* 2019; 53: 1802243.
- 14 Ishii H, Watanabe K, Kushima H, et al. Pleuroparenchymal fibroelastosis diagnosed by multidisciplinary discussions in Japan. *Respir Med* 2018; 141: 190–197.
- 15 Nakamura Y, Mori K, Enomoto Y, et al. Prognostic and clinical value of cluster analysis in idiopathic pleuroparenchymal fibroelastosis phenotypes. *J Clin Med* 2021; 10: 1498.
- 16 Suzuki Y, Fujisawa T, Sumikawa H, et al. Disease course and prognosis of pleuroparenchymal fibroelastosis compared with idiopathic pulmonary fibrosis. *Respir Med* 2020; 171: 106078.
- 17 Raghu G, Remy-Jardin M, Myers JL, et al. Diagnosis of idiopathic pulmonary fibrosis. An official ATS/ERS/JRS/ALAT clinical practice guideline. *Am J Respir Crit Care Med* 2018; 198: e44–e68.
- 18 Hirota T, Yoshida Y, Kitasato Y, et al. Histological evolution of pleuroparenchymal fibroelastosis. *Histopathology* 2015; 66: 545–554.